

# The effect of intraocular pressure lowering medications on the pressure spike associated with intravitreal injection

Olya Pokrovskaya, MBBChBAO; Ian Dooley, MSc; Salma Babiker, MBBS; Catherine Croghan, MBBChBAO; Claire Hartnett, MSc; Anthony Cullinane

Department of Ophthalmology, Cork University Hospital, Cork, Ireland

## Abstract

**Purpose.** This study investigates whether the post intravitreal injection intraocular pressure (IOP) spike is modifiable with the use of prophylactic apraclonidine and dorzolomide.

**Methods.** The study design is a prospective, randomized controlled clinical trial. 80 eyes undergoing intravitreal injection of anti-VEGF agent were studied. A control group (n = 42) received no IOP lowering drops, and a study group (n = 38) received topical apraclonidine and dorzolamide 30 to 40 minutes before the intravitreal injection. IOP measurements were taken in both groups using the Perkins tonometer at baseline, immediately before and after the injection, 5 minutes post-injection, and 15 minutes post-injection.

**Results.** Mean IOP immediately post injection in the study group compared to the control group was lower: 26.71 mmHg versus 32.73 mmHg (p=0.026). The main outcome measure was the area under the curve (AUC), reflecting the trend of IOP post injection. The AUC was lower in the study group compared to the control group (Mann-Whitney U test, p=0.046).

**Conclusions.** The use of prophylactic apraclonidine and dorzolamide is effective in modifying the post-injection IOP spike. IOP

lowering prophylaxis may be considered in patients with a high baseline IOP.

## Introduction

Among the most exciting and innovative ophthalmological advances in recent years is the introduction of intravitreal injection of anti-VEGF drugs. These drugs have been shown to be sight-saving in a variety of retinal pathologies, including exudative age-related macular degeneration and diabetic macular edema.<sup>1-3</sup> One of the established side-effects of intravitreal injection is a temporary rise in the intraocular pressure (IOP).<sup>4-6</sup> This increase has been attributed to volume expansion; however, the exact mechanism remains unclear.<sup>7,8</sup> Even a short-lived spike in the IOP can have potentially devastating consequences on an eye that may be already compromised in terms of its vasculature. The Royal College of Ophthalmologists recommend routinely checking that the patient can see objects immediately after the injection, to ensure that the central retinal artery is patent (<http://www.rcophth.ac.uk>). Routine IOP measurement before and after injection may not be necessary; however, it should be considered in certain patients at risk of having a high IOP.<sup>9</sup>

### Correspondence:

Olya Pokrovskaya, MBBChBAO  
Department of Ophthalmology  
Mater Misericordiae University Hospital  
Dublin, Ireland  
E-mail: olya.pokrovskaya@gmail.com  
Phone: 353-87-6149912

**Conflict of Interest:** The authors report no conflicts of interest.

**Contributions:** All authors contributed equally.

**Accepted for Publication:** February, 2018

This work is licensed under a Creative Commons Attribution

Non-Commercial 3.0 License (CC BY-NC 3.0).

©Copyright Pokrovskaya et al., 2018.

Licensee Ophthosience Publishers, USA

Several authors have addressed the issue of prophylaxis in reducing the post-injection IOP spike. Frenkel, et al. carried out a retrospective study of 71 patients, which did not show any significant benefit of pressure-lowering medications.<sup>10</sup> El Chehab, et al. prospectively evaluated different regimens in 210 patients and showed a significant reduction in the pressure spike with several topical medications but not with oral acetazolamide.<sup>11</sup> Theoulakis, et al. reported on a series of 88 patients and found a reduction of the pressure spike after the use of brimonidine/timolol.<sup>12</sup> To date, no treatment regimen has been established as clearly effective and beneficial for patients undergoing intravitreal injection. Indeed, the question remains whether it is at all advantageous to use prophylactic pressure lowering medications prior to intravitreal injections, and if so, in which patients. The objective of our study was to determine whether the IOP spike is modifiable by the prophylactic use of the combination of dorzolamide and apraclonidine 1%. Both of these drugs are readily available in single dose units, which is useful in reducing the risk of infection.

## Materials and Methods

A prospective, randomized controlled trial was performed between October 2011 and April 2012 in a single treatment center. Ethical approval was obtained from the Clinical Research Ethics Committee of the Cork Teaching Hospitals.

Eighty consecutive patients due to undergo intravitreal injection of 0.05ml of ranibizumab (0.5mg/0.05ml) for a variety of retinal pathologies were included in the study. Exclusion criteria included a history of ocular hypertension or glaucoma and intravitreal injection of agents other than ranibizumab. Only one eye per patient was included. Written informed consent was obtained from all patients.

A random number generator assigned patients to either study or control group before the injection. The control group received no IOP lowering medications. The study group received one drop of topical 1% apraclonidine and one drop of topical 2.0%

dorzolamide at 30 to 40 minutes before the injection. IOP measurements were taken with the Perkins tonometer (Clement Clarke, Essex, United Kingdom) at baseline before the administration of drops (T-0). Subsequent measurements were 1 minute before injection (T-1), 2 minutes after injection (T-2), 5 minutes after injection (T-3), and 15 minutes after injection (T-4). To minimize inter-observer error, the same physician carried out all measurements for a given patient, (there were 4 such physicians over the 6-month period of data collection). Physicians were not blinded to the group of the patient. The IOP measurement technique and endpoint were clearly defined and standardized for all physicians involved prior to data collection. The identical injection technique of 0.05ml of ranibizumab was used across all cases. A sterile cotton tip was applied to the injection site to prevent subconjunctival reflux. In between IOP measurements, the tonometer was made aseptic using alcohol swabs, and then dried using sterile gauze. One drop of topical chloramphenicol was administered after each IOP measurement.

The main outcome measure was the area under the curve (AUC) with respect to ground. This method is useful for detecting possible associations between repeated measures and other variables, over several time points.<sup>13</sup> We calculated the AUC using a formula derived from the trapezoid formula, whereby the individual measurements used were the mean IOP values for study and control groups, and the individual time distance between the measurements was the injection-relative times.

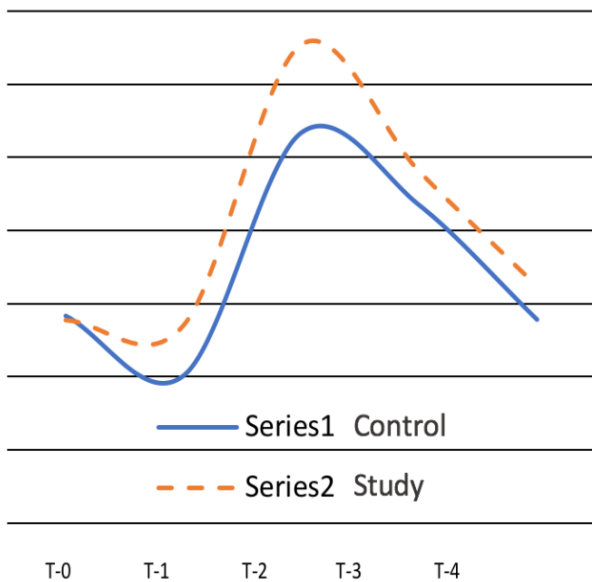
Statistical analysis was carried out using Statistical Package for the Social Science IBM SPSS Statistics Version 18 (IBM Corporation, Armonk, New York). Data was tested for normality using the Shapiro-Wilk test and the appropriate statistical tests used to compare means— independent samples t test for parametric data, and Mann-Whitney U test for non-parametric data. A p value less than .05 was considered statistically significant.

## Results

The mean age was 72 years in the study group, and 71 years in the control group. The study and control groups did not differ significantly in terms of baseline IOP, with a mean ( $\pm$  standard deviation) of 14.17 ( $\pm$  3.82) mmHg in the study group and 13.88 ( $\pm$  3.83) mmHg in the control group ( $p = .77$ ).

Thirty to forty minutes post administration of IOP lowering prophylaxis (and immediately pre-injection), the patients in the study group showed a mean IOP drop of 4.09 mmHg (Figure 1, Table 1). The study group had a significantly different mean IOP of 10.08 mmHg in comparison to the control group's mean IOP of 13.53 mmHg, with a  $p$  value of .001 (Independent samples  $t$  test).

The mean IOP immediately post injection in the study group was 26.71 mmHg as compared to 32.73 mmHg in the control group. Using the mean values for study and control groups at T-1 to T-4 we constructed a curve and calculated the AUC. The



**Figure 1**

IOP for the control and study groups varied over time, and remained lower for the study group as compared to the case group. The time intervals are baseline (T-0), immediately before the injection (T-1), immediately after the injection (T-2), 5 minutes after the injection (T-3), and 15 minutes after the injection (T-5).

Interval	Study Group Mean IOP $\pm$ SD	Control Group Mean IOP $\pm$ SD	Mean Difference Between Groups (95% CI)	$p$ Value*
T-0 (baseline)	14.17 $\pm$ 3.82	13.88 $\pm$ 3.83	0.29 (-1.68 to 2.27)	0.769
T-1 (pre injection)	10.08 $\pm$ 3.61	13.53 $\pm$ 3.66	-3.44 (-5.32 to -1.56)	0.001
T-2 (immediately post injection)	26.71 $\pm$ 10.36	32.37 $\pm$ 9.79	-6.02 (-11.29 to -0.74)	0.026
T-3 (5 minutes post injection)	21.75 $\pm$ 8.42	24.95 $\pm$ 8.06	-2.30 (-6.61 to 2.01)	0.288
T-4 (15 minutes post injection)	13.92 $\pm$ 3.35	16.20 $\pm$ 5.76	-2.28 (-4.57 to -0.01)	0.049

**Table 1**

The mean IOP differed between the study and control groups at various time intervals. The time intervals are baseline (T-0), immediately before the injection (T-1), immediately after the injection (T-2), 5 minutes after the injection (T-3), and 15 minutes after the injection (T-5).

values for AUC were not normally distributed (Shapiro-Wilke,  $p = .053$ ), so a non-parametric test was used to compare the study and control groups (Mann-Whitney U test). The study group had a lower AUC than the control group (Mann-Whitney U test,  $p = .046$ ).

A significant positive correlation was found between T-1 (IOP immediately pre-injection) and the AUC (Kendel's tau:  $r = 0.268$ ;  $p < 0.001$ ). Data on axial length was available for 15 patients. No significant correlation emerged between the IOP spike and the axial length (Pearson's correlation:  $r = -.001$ ;  $p = 0.997$ ).

In both the study and control groups, the IOP showed rapid normalization post-injection. 79 of 80 eyes had an IOP of less than 30 mmHg within 15 minutes post injection. The one patient who did not have an IOP of less than 30 mmHg within 15 minutes post injection was in the control group and achieved an IOP of 28 mmHg twenty minutes following injection.

## Discussion

An acutely increased IOP in an eye with compromised vasculature is one of the most hazardous perioperative complications of intravitreal injection. Prophylactic IOP lowering medications are effective in preventing IOP spikes following procedures such as ALT-trabeculoplasty and nd:YAG laser capsulotomy.<sup>14-16</sup> To our knowledge, this study is the first prospective, randomized controlled trial investigating the effect of dorzolamide and apraclonidine on the post intravitreal injection IOP spike.

In this study a single regimen was used: the combination of dorzolamide and apraclonidine. These agents are available in single-dose formulation and hence are a cost-effective method of reducing intraocular pressure when only a single administration is required in each patient. The extent of IOP reduction recorded with this combination is dramatic: within 30 minutes after administration of these two topical IOP-lowering agents, the IOP was reduced from 14.17 mmHg to 10.08 mmHg (approximately a 28% reduction). Such a pronounced reduction in IOP at just 30 minutes is greater than expected, and perhaps this phenomenon was due to the concurrent administration of local anaesthetic drops and their effect on corneal permeability; however, no conclusive support for this hypothesis was found in the literature.

This study suggests that a lower starting IOP pre-injection is associated with lower pressure following the injection. Glaucoma and ocular hypertension patients were excluded from this study, as inclusion may have confounded the results. Erratic diurnal IOP fluctuation is more common in eyes with glaucoma and ocular hypertension than in healthy eyes; hence, the IOP may be more likely to reach a higher peak post intravitreal injection.<sup>17</sup> To the patients included in this study, prophylaxis has little clinical advantage—data showed that in both study and control groups, the IOP spike was transient with the vast majority of patients returning to a pressure of less than 25 mmHg within 15 minutes post-injection. This finding is similar to that of other authors, all of

whom found the IOP spike to be short lived.<sup>4, 11, 18, 19</sup> It is important to note that the difference in IOP between the study and control groups was less at 5 minutes and 15 minutes post injection as compared to immediately before and after injection. This finding has been reported previously in the literature,<sup>11</sup> though a plausible explanation for this phenomenon remains elusive.

In Frenkel, et al.'s study, the post injection IOP spike was higher than this study. This discrepancy may be partially explained by the particularly high number of glaucoma patients included in Frenkel, et al.'s study. Furthermore, some of the patients in Frenkel, et al.'s study received high volume injections, namely of 0.09 ml pegaptanib versus the 0.05 ml injection volume of ranibizumab; therefore, finding that patients who received the higher volume pegaptanib injection had generally higher IOP spikes is not surprising.

It is uncertain, though, why the post-injection IOP spike is much greater in some patients than others. Possible factors which influence the magnitude of the post-injection IOP spike include pre-existing glaucoma (excluded from this study), axial length, age, and subconjunctival reflux of synergetic vitreous and/or drug.

The magnitude of the IOP spike post-injection may be related to the axial length, since the injection of 0.05 ml into a smaller, hyperopic eye would represent a greater proportion of the total ocular volume than in a larger emmetropic or myopic eye. Data on axial length was only available on 15 of the 80 participants in this study and did not show a significant correlation between magnitude of IOP spike and axial length.

The phakic status of patients may also be a determinant of the magnitude of post-injection IOP spike, since, during intravitreal injection in phakic patients, the lens-iris diaphragm may shift forward and reduce aqueous outflow. El Chehab, et al. recorded the axial length and phakic status of patients and did not find a significant correlation between the IOP spike and either of these variables.<sup>11</sup>



The role of age may be considered a confounding factor. A positive correlation between ocular rigidity and age has been reported in the medical literature.<sup>20</sup> It is reasonable to suppose that older eyes may have less ocular compliance, and hence respond with a greater IOP spike to ocular volume increase. However, the data from this study showed no such correlation.

The strength and advantage of this study lie largely in its prospective nature. Consistent technique is used for all injections and IOP measurements, lending reliability to the findings. Limitations of this study include the limited number of patients: greater patient numbers are needed to more accurately determine the possible factors leading to adverse IOP spikes. This study is not double-blind, which allows for potential bias in the measurements.

## Conclusion

This study demonstrates the effect of relatively mild IOP prophylaxis. Furthermore, this study adds to the body of evidence that prophylaxis is unnecessary in those without glaucoma or ocular hypertension who are undergoing intravitreal injection of 0.05 ml. Given current evidence that the patients with glaucoma may have greater IOP fluctuations than those without glaucoma, and that the optic nerves of glaucomatous eyes are sensitive to these IOP fluctuation, future studies should focus specifically on the magnitude, duration, modifiability and potential deleterious effects of the post-injection spike in glaucomatous eyes.<sup>17, 21-23</sup> A future trial could also examine the rate of visual field progression in patients with glaucoma who are also receiving serial intravitreal injections, versus those who are not.

## References

1. Bloch SB, Larsen M, Munch IC. Incidence of legal blindness from age-related macular degeneration in Denmark: year 2000 to 2010. *Am J Ophthalmol.* 2012; 153: 209-13.
2. Bressler NM, Doan QV, Varma R, et al. Estimated cases of legal blindness and visual impairment avoided using ranibizumab for choroidal neovascularization: non-Hispanic white population in the United States with age-related macular degeneration. *Arch Ophthalmol.* 2011; 129: 709-17.
3. Skaat A, Chetrit A, Belkin M, et al. Time trends in the incidence and causes of blindness in Israel. *Am J Ophthalmol.* 2012;153:214-21 e1.
4. Falkenstein IA, Cheng L, Freeman WR. Changes of intraocular pressure after intravitreal injection of bevacizumab (Avastin). *Retina.* 2007; 27: 1044-7.
5. Wu L, Evans T. [Immediate changes in intraocular pressure after an intravitreal injection of 2.5 mg of bevacizumab]. *Arch Soc Esp Ophthalmol.* 2010; 85: 364-9.
6. Sharei V, Hohn F, Kohler T, et al. Course of intraocular pressure after intravitreal injection of 0.05 mL ranibizumab (Lucentis). *Eur J Ophthalmol.* 2010; 20: 174-9.
7. Hariprasad SM, Shah GK, Blinder KJ. Short-term intraocular pressure trends following intravitreal pegaptanib (Macugen) injection. *American J Ophthalmol.* 2006; 141: 200-1.
8. Rosenfeld PJ, Brown DM, Heier JS, et al. Ranibizumab for neovascular age-related macular degeneration. *N Engl J Med.* 2006; 355: 1419-31.
9. Aiello LP, Brucker AJ, Chang S, et al. Evolving guidelines for intravitreal injections. *Retina.* 2004; 24: S3-19.
10. Frenkel MP, Haji SA, Frenkel RE. Effect of prophylactic intraocular pressure-lowering medication on intraocular pressure spikes after intravitreal injections. *Arch Ophthalmol.* 2010; 128: 1523-7.
11. El Chehab H, Le Corre A, Agard E, et al. Effect of topical pressure-lowering medication on prevention of intraocular pressure spikes after intravitreal injection. *Eur J Ophthalmol.* 2013; 23: 277-83.
12. Theoulakis PE, Lepidas J, Petropoulos IK, et al. Effect of brimonidine/timolol fixed combination on preventing the short-term intraocular pressure increase after intravitreal injection of ranibizumab. *Klin Monbl Augenheilkd.* 2010; 227: 280-4.
13. Pruessner JC, Kirschbaum C, Meinlschmid G, Hellhammer DH. Two formulas for computation of the area under the curve represent measures of total hormone concentration versus time-dependent change. *Psychoneuroendocrinology.* 2003; 28: 916-31.
14. Robin AL, Pollack IP, House B, Enger C. Effects of ALO 2145 on intraocular pressure following argon laser trabeculoplasty. *Arch Ophthalmol.* 1987; 105: 646-50.

15. Barnes SD, Campagna JA, Dirks MS, Doe EA. Control of intraocular pressure elevations after argon laser trabeculoplasty: comparison of brimonidine 0.2% to apraclonidine 1.0%. *Ophthalmol.* 1999; 106: 2033-7.
16. Ladas ID, Baltatzis S, Panagiotidis D, et al. Topical 2.0% dorzolamide vs oral acetazolamide for prevention of intraocular pressure rise after neodymium:YAG laser posterior capsulotomy. *Arch Ophthalmol.* 1997; 115: 1241-4.
17. Wilensky JT, Gieser DK, Dietsche ML, et al. Individual variability in the diurnal intraocular pressure curve. *Ophthalmol.* 1993; 100: 940-4.
18. Kim JE, Mantravadi AV, Hur EY, Covert DJ. Short-term intraocular pressure changes immediately after intravitreal injections of anti-vascular endothelial growth factor agents. *Am J Ophthalmol.* 2008; 146: 930-4.
19. Hollands H, Wong J, Bruen R, et al. Short-term intraocular pressure changes after intravitreal injection of bevacizumab. *Can J Ophthalmol.* 2007; 42: 807-11.
20. Pallikaris IG, Kymionis GD, Ginis HS, et al. Ocular rigidity in living human eyes. *Invest Ophthalmol Vis Sci.* 2005; 46: 409-14.
21. Detry-Morel M. Currents on target intraocular pressure and intraocular pressure fluctuations in glaucoma management. *Bull Soc Belge Ophthalmol.* 2008; 308: 35-43.
22. Realini T, Barber L, Burton D. Frequency of asymmetric intraocular pressure fluctuations among patients with and without glaucoma. *Ophthalmol.* 2002; 109: 1367-71.
23. Zeimer RC, Wilensky JT, Gieser DK, Viana MA. Association between intraocular pressure peaks and progression of visual field loss. *Ophthalmol.* 1991; 98: 64-9.

# Trabeculectomy with an implantable biodegradable collagen matrix (Ologen) for the management of glaucoma associated with cavernous sinus arteriovenous fistula

Isha Gulati Grover, MD; Sirisha Senthil, MD, PhD; Garudadri Chandrasekhar, MD.

Department of Ophthalmology, LV Prasad Eye Institute, Hyderabad, India.

## Abstract

A 58-year-old gentleman presented with open angle glaucoma secondary in the right eye secondary to a cavernous sinus arteriovenous fistula. Since the intraocular pressure control was refractory to medical management, an augmented filtration surgery was planned. Trabeculectomy in eyes with raised episcleral venous pressure is associated with a substantially greater risk of intraoperative or post-operative choroidal effusion and suprachoroidal haemorrhage. This patient was successfully managed by performing trabeculectomy with an implantable biodegradable collagen, type 1 atelocollagen, matrix (Ologen), without any sight threatening complications.

## Introduction

Secondary glaucoma occurs in nearly half of the patients who have ophthalmic manifestations of cavernous sinus arteriovenous fistulae.<sup>1</sup> Elevated intraocular pressure (IOP) is secondary to increased episcleral venous pressure. Glaucoma is the most common cause of loss of vision in these eyes and is often challenging to treat. With trabeculectomy, there is a high risk of potentially vision-threatening intraoperative or post-operative complications such as suprachoroidal hemorrhage or choroidal effusion.<sup>2</sup>

The adjunctive use of anti-fibrotics to prevent post-operative scarring enhances the long-term success rate of trabeculectomy; however, it may be associated with a greater incidence of post-operative hypotony which is detrimental in eyes with raised episcleral venous pressure.<sup>3</sup> An implantable biodegradable collagen matrix designed for sub-conjunctival placement to enhance the long term success of trabeculectomy may be a safer alternative in these eyes. It not only modulates post-operative sub-conjunctival fibrosis, but it may keep the scleral flap mechanically well apposed, preventing over filtration and hypotony. The Ologen collagen matrix (Aeon Astron Europe BV, Leiden, Netherlands) is a porous scaffold of 90% or more porcine type 1 atelocollagen and 10% or less glycosaminoglycans. This report demonstrates the successful management with trabeculectomy and Ologen implant of a patient with refractory open angle glaucoma secondary to a cavernous sinus arteriovenous fistula.

## Case Report

A 58-year-old gentleman presented with a chief complaint of decreased vision associated with pain and redness in the right eye over the two years prior to his presentation. One year prior to presentation, he

### Correspondence:

Sirisha Senthil, MD, PhD  
Centre for Glaucoma, LV Prasad Eye Institute  
Kallam Anji Reddy Campus  
L V Prasad Marg, Hyderabad, India 500 034  
Email: sirishasenthil@lvei.org  
Phone: 91 040 30612631

**Conflict of Interest:** The authors report no conflicts of interest.

**Contributions:** All authors contributed equally.

**Accepted for Publication:** February, 2018

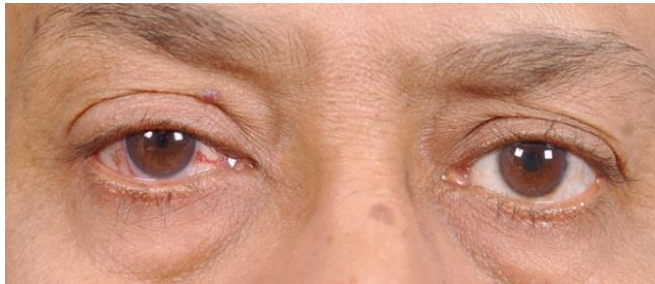This work is licensed under a Creative Commons Attribution Non-Commercial 3.0 License (CC BY-NC 3.0).

©Copyright Grover, et al., 2018.

Licensee Ophthosience Publishers, USA

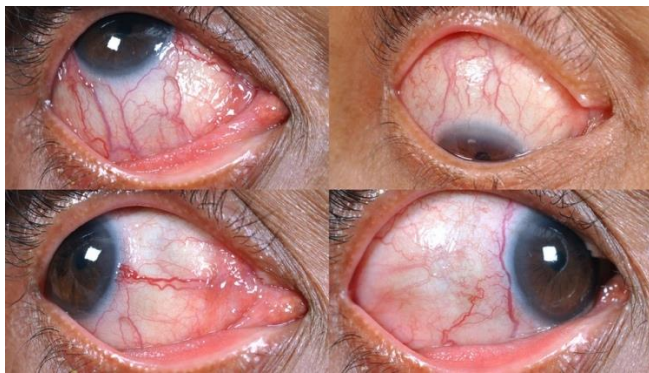was diagnosed elsewhere with open angle glaucoma in the right eye and was started on the following treatment regimen: topical 2% dorzolamide one drop three times per day, topical combination 0.5% timolol maleate with 4% pilocarpine one drop two times per day, and topical 0.005% latanoprost one drop once at bedtime. He has a medical history of well-controlled diabetes and hypertension. He has history of head trauma with a wooden stick 18 years prior to presentation.

Best corrected visual acuity was 20/40 in the right eye and 20/20 in the left eye. On clinical examination, extraocular movements were full, orthophoric, and painless in all directions of gaze. A right-sided subtle axial proptosis was present (Figure 1). Anterior



**Figure 1**  
*Axial proptosis of the right side was present.*

segment examination revealed dilated, tortuous corkscrew shaped episcleral vessels in the right eye (Figure 2). The anterior segment was unremarkable in the left eye.



**Figure 2**  
*Dilated and tortuous episcleral vessels were present in all quadrants.*

IOP was 26 mmHg and 14 mmHg in the right and left eyes, respectively. The central corneal thickness was 523 and 542 microns in the right and left eyes, respectively. The anterior chamber angle was open up to scleral spur in both eyes. There was no evidence of angle recession or blood in the Schlemm's canal in either eye. Orbital bruit and signs of thyroid eye disease were absent.

Dilated fundus examination revealed an average sized disc, with a vertical cup-to-disc ratio of 0.9 in the right eye, with bipolar notching. The disc was within normal limits in the left eye. Formal visual field testing (Humphrey Visual Field Analyzer 10-2 SITA-Standard) demonstrated a biarcuate scotoma threatening fixation in the right eye. Perimetry was within normal limits in the left eye.

Orbital imaging revealed a dilated superior ophthalmic vein in the right orbit as well as thickening of the right medial rectus muscle. In view of history of trauma, a clinical diagnosis of a cavernous sinus arteriovenous fistula was made. The patient's open angle glaucoma of a right eye was posited to be secondary to the cavernous sinus fistula.

Since the IOP was uncontrolled despite maximally tolerated medical therapy, surgical intervention was planned. Trabeculectomy with an Ologen collagen matrix was performed.

To reduce IOP and prevent sudden hypotony, pre-operative injection of intravenous 20% mannitol was administered to the patient. A standard fornix based trabeculectomy with wide area dissection and triangular scleral flap was performed. The flap was sutured at the apex using a single 10-0 nylon suture. The suture was normotensive and just apposed the flap to the scleral bed. A 6 mm Ologen disc was positioned subconjunctivally, allowing it to partly cover the apex of the triangular scleral flap. Watertight conjunctival closure was achieved using interrupted 8-0 polyglactin sutures. Cycloplegics were initiated at the conclusion of the surgery to deepen the anterior chamber. There were no intraoperative complications.

On post-operative day one, the patient's visual acuity was 20/60. IOP was 16 mmHg. Anterior

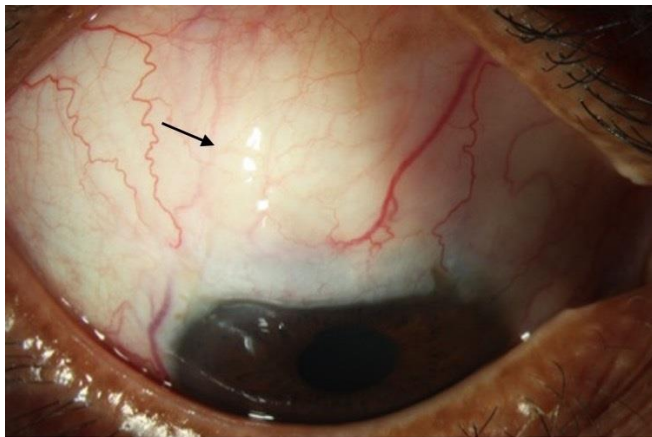


segment examination disclosed a diffuse bleb and deep and well-formed anterior chamber. The patient was started on topical 1% prednisolone acetate one drop eight times per day, topical 0.5% moxifloxacin one drop four times per day, and topical 1% cyclopentolate one drop three times per day.

However, one week post-operatively, examination disclosed a formed but mildly uniformly shallow anterior chamber, in the presence of a diffuse bleb. Seidel's test was negative and the IOP was noted to be 14 mmHg. Fundus examination revealed peripheral shallow choroidal detachment, confirmed B-scan ultrasonography. In addition to the intensive topical steroids, the additional cycloplegic and mydriatic agents were added.

By one month post-operatively, the choroidal detachment resolved and the anterior chamber deepened to normal. The patient's visual acuity improved to 20/20 and IOP was 16 mmHg.

Two years post-operatively, the IOP has been well maintained with a well-functioning, diffuse bleb (Figure 3) without any topical intraocular pressure lowering agents. Visual acuity and perimetry have also remained stable over two years.



**Figure 3**  
*Anterior segment examination one year post-operative revealed a diffuse, well-functioning bleb in the right eye.*

## Discussion

Cavernous sinus fistulae are characterized by an arteriovenous communication between the cavernous

sinus and the internal or external carotid artery, or both. These may occur insidiously in the setting of systemic disease such as hypertension or atherosclerosis, or they may occur abruptly following trauma. Most fistulae, which are traumatic in origin, have high rates of arterial blood flow, though some have low flow rates. Presenting features may include decreased vision, diplopia from ophthalmoparesis, proptosis, including pulsatile proptosis, conjunctival chemosis, and dilated and tortuous conjunctival vessels. However, the presenting features are often subtle and easy to overlook. Often times, patients are misdiagnosed with blepharitis, conjunctivitis, or even thyroid eye disease. In this case, the patient was initially misdiagnosed as having primary open angle glaucoma, even though he had open angle glaucoma secondary to the cavernous sinus fistula.

The incidence of secondary glaucoma in patients with cavernous sinus arteriovenous fistulae ranges from 41% - 64.3% in various studies.<sup>1</sup> Intractable secondary glaucoma in these eyes is the major cause of ocular morbidity and requires prompt treatment. While closure of the fistula is often the definitive treatment, if the fistula does not spontaneously close, surgical treatment of the glaucoma is an option. However, surgical management of these eyes is extremely challenging, as these patients usually have an aggressive course of disease and need long-term substantially lowered post-operative IOP. In addition, the sudden lowering of IOP in eyes with raised episcleral venous pressure may lead to serous or haemorrhagic transudation into the suprachoroidal space due to unopposed venous backpressure. Thus, these patients are at a higher risk of intraoperative and post-operative complications such as choroidal effusion, suprachoroidal haemorrhage, and hypotony maculopathy, all of which may be potentially vision threatening.<sup>2</sup>

In view of long standing disease, increased conjunctival vascularity, and use of multiple topical medications, the probability of post trabeculectomy fibrosis was very high in this patient. Adjuvant use of anti-metabolites is an option in these patients, as it has been demonstrated to significantly improve the

long term success of trabeculectomy. However, the incidence of hypotony related complications is increased with the use of anti-metabolites.<sup>3</sup> Other options in these situations include the use of releasable sutures with trabeculectomy.

Trabeculectomy with Ologen implant was chosen as it not only modulates post-operative sub-conjunctival fibrosis, but also mechanically keeps the scleral flap well apposed to decrease the risk of post-operative hypotony. Ologen is a biodegradable implant consisting primarily of atelocollagen, designed for sub-conjunctival placement. It acts as a mechanical separator and prevents conjunctival fibrosis with the episcleral tissue. It also helps in tissue remodeling and organized wound healing post-operatively.<sup>4</sup> A meta-analysis of 6 studies including 224 participants concluded that trabeculectomy with an Ologen implant is comparable to the use of the anti-metabolite mitomycin C, with a similar long-term success rates.<sup>5</sup>

Based on our experience, we believe that the 6 mm Ologen disc should be positioned at the apex of the triangular flap or over the posterior edge of the rectangular flap. We believe that care should be taken to avoid placing the Ologen disc closer the base of the scleral flap, which may result in increased mechanical resistance, sub-scleral adhesions and eventually bleb failure. We believe that placement of the disc should be followed by meticulous conjunctival closure with 8-0 polyglactin suture.

## Conclusion

Refractory secondary glaucoma in eyes with raised episcleral venous pressure may be challenging

to manage. Trabeculectomy in these eyes is associated with increased risk of intraoperative and post-operative complications. Use of collagen implants that not only modulate post-operative wound healing but also prevent post-operative hypotony may be beneficial. A biodegradable collagen matrix implant may mechanically keep the scleral flap well apposed, thus preventing over filtration and hypotony. We believe that the Ologen implant may be a safe alternative in this subset of high risk patients, including high myopes, juvenile open angle glaucomas, and glaucomas associated with raised episcleral venous pressure.

## References

1. Ishijima K, Kashiwagi K, Nakano K, Shibuya T, Tsumura T, Tsukahara S. Ocular manifestations and prognosis of secondary glaucoma in patients with carotid-cavernous fistula. *Japanese journal of ophthalmology*. 2003;47(6):603-8.
2. Bellows AR, Chylack LT, Jr., Epstein DL, Hutchinson BT. Choroidal effusion during glaucoma surgery in patients with prominent episcleral vessels. *Archives of Ophthalmology*. 1979;97(3):493-7.
3. Bindlish R, Condon GP, Schlosser JD, D'Antonio J, Lauer KB, Lehrer R. Efficacy and safety of mitomycin-C in primary trabeculectomy: five-year follow-up. *Ophthalmology*. 2002;109(7):1336-41; discussion 41-2.
4. Chen HS, Ritch R, Krupin T, Hsu WC. Control of filtering bleb structure through tissue bioengineering: An animal model. *Investigative Ophthalmology and Visual Science*. 2006;47(12):5310-4.
5. Ji Q, Qi B, Liu L, Guo X, Zhong J. Efficacy and Safety of Ologen Implant Versus Mitomycin C in Primary Trabeculectomy: A Meta-analysis of Randomized Clinical Trials. *Journal of Glaucoma*. 2015;24(5):e88-94.

# Spectral domain optical coherent tomography demonstrates structural retinal changes in isolated cilioretinal artery occlusion

Mansooreh Bagheri, MD; Hosein Ashraf, MD; Mohammad Hosein Nowroozzadeh, MD

Shiraz University of Medical Sciences, Shiraz, Iran

## Abstract

This report demonstrates the structural retinal changes observed *in-vivo* by spectral domain optical coherent tomography (SD-OCT) in a case of isolated cilioretinal artery occlusion. A 32-year-old woman presented one week following acute sudden painless loss of vision. Ophthalmoscopy revealed macular edema and a cherry red spot. Fluorescein angiography one week post-infarction demonstrated a large patch of macular hypofluorescence in the distribution of the cilioretinal artery, with perfusion of the cilioretinal artery. Within this same macular distribution, SD-OCT demonstrated increased reflectivity, with increased reflectivity of the inner nuclear, inner plexiform, and ganglion cell layers. A sharp boundary was present between normal and infarcted macula on SD-OCT imaging. SD-OCT is a useful tool for diagnosing and identifying the extent of retinal vascular occlusion.

## Introduction

Isolated cilioretinal artery occlusion is a rare condition, comprising 5% of all retinal arterial occlusions.<sup>1,2</sup> Mechanisms underlying cilioretinal artery occlusion are either a reduction in perfusion pressure, often from embolus, or a mechanical compression of the artery as a result of an increase in venous pressure.<sup>3</sup> The three clinical settings in which cilioretinal artery occlusions are: (1) an isolated

arterial occlusive event, (2) an occlusive event associated with venous occlusion, specifically a central retinal vein occlusion, mechanically compressing the artery, and (3) an occlusive event associated with anterior ischemic optic neuropathy, often arteritic, namely as a result of giant cell arteritis.<sup>4</sup> The cilioretinal artery and its occlusion may be diagnosed by funduscopy, fluorescence angiography, optical coherent tomography (OCT) imaging, as well as OCT angiography.<sup>5</sup> This report demonstrates the structural retinal changes observed *in-vivo* by spectral-domain OCT (SD-OCT) in a case of isolated cilioretinal artery occlusion.

## Case Report

A 32-year-old woman presented one week following acute sudden painless loss of vision in her left eye. The patient's past medical history and family history were unremarkable. Her best corrected visual acuity (BCVA) was count fingers at half a meter in the left eye and was 20/20 in the right eye. On clinical examination, the anterior segment in each eye was unremarkable and intraocular pressure in each eye was within a healthy range. Fundus examination of the left eye demonstrated macular edema with retinal opacification throughout the central macula in an area approximately 2 to 3 disc diameters in radius around the fovea. There was a central cherry red spot. There

### Correspondence:

Mansooreh Bagheri, MD  
Department of Ophthalmology  
Pootschi Ophthalmology Research Center  
Zand Avenue, Shiraz, Iran  
Email: mansooreh\_bagheri@yahoo.com  
Phone: 00989173201260

**Conflict of Interest:** The authors report no conflicts of interest.

**Contributions:** All authors contributed equally.

**Accepted for Publication:** February, 2018

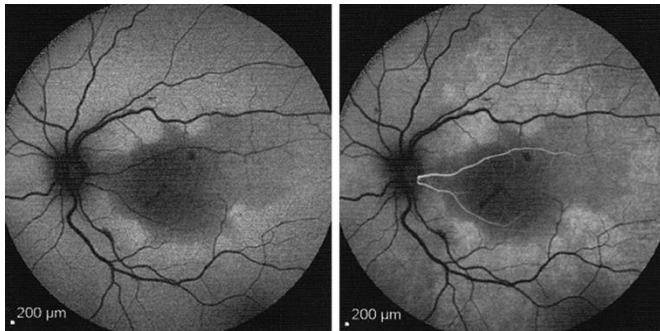
This work is licensed under a Creative Commons Attribution Non-Commercial 3.0 License (CC BY-NC 3.0).

©Copyright Bagheri, et al., 2018.

Licensee Ophthosience Publishers, USA

was no retinal hemorrhage or exudate. The retinal vasculature appeared normal.

Fluorescein angiography (FA) of the left eye revealed a large double branch cilioretinal artery perfusing the main parts of the macular area (Figure 1). Although the cilioretinal arteries were patent on FA, retinal ischemia along the distribution of these arteries was indicative of previous occlusion of the double branch cilioretinal artery. No other pathologic changes were observed on FA of the left eye.

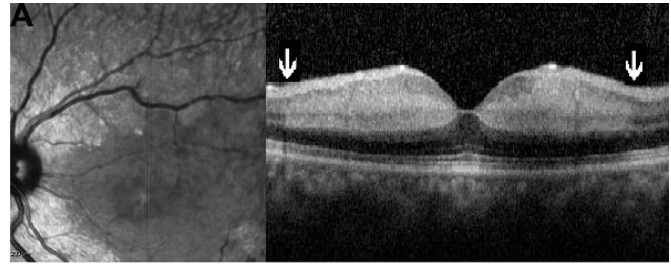


**Figure 1**

*Fluorescein angiography in choroidal flush phase shows a large hypofluorescent area due to macular edema. A double branch cilioretinal artery perfuses the main parts of this area. Retinal ischemia along the distribution of these arteries is indicative of previous occlusion of the cilioretinal artery.*

The structural changes of macular area were evaluated by SD-OCT (version 5.4.6 software, Spectralis OCT, Heidelberg engineering, Heidelberg, Germany), which revealed increased reflectivity of the inner nuclear, inner plexiform, and ganglion cell layers in the involved parts of the macula, as well as increased retinal thickness with a normal looking general contour in the parafoveal and perifoveal areas (Figure 2). Noticeably, on SD-OCT imaging, there was a sharp border between the infarcted and non-infarcted portions of retina.

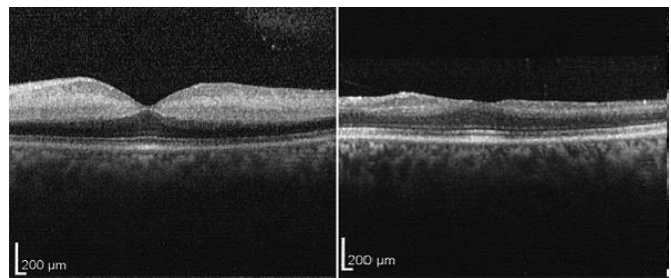
Formal visual field testing (Humphrey Visual Field Analyzer 30-2 SITA-FAST) of the left eye demonstrated poor fixation and confirmed a large central scotoma. Systemic evaluations were unremarkable.



**Figure 2**

*SD-OCT in acute phase demonstrated increased reflectivity and thickness of the inner nuclear, inner plexiform, and ganglion cell layers in the involved parts of macular areas. SD-OCT also demonstrated a sharp border (white arrows) between the infarcted and non-infarcted portions of retina.*

Two months after onset, the patient's visual symptoms persisted and examination of the left eye revealed atrophic changes in macular area. SD-OCT demonstrated profound thinning and decreased reflectivity of the parafoveal inner retinal layers with loss of the foveal depression (Figure 3).



**Figure 3**

*Comparison of SD-OCT of macular area taken 1 week (left image) and 2 months (right image) after cilioretinal artery occlusion revealed profound change over a 2 month period. SD-OCT imaging at 2 months demonstrated decreased reflectivity and thinning of the parafoveal inner retinal layers and loss of the foveal depression.*

## Discussion

Cilioretinal artery occlusion is a rare condition, which is often diagnosed by funduscopy and fluorescence angiography.<sup>1</sup> Specific anatomical bifurcation, lower perfusion pressure compared to the central retinal artery, and lack of self-regulation of this



perfusion pressure make the cilioretinal artery vulnerable to occlusion.<sup>2</sup>

SD-OCT is a non-invasive, high-resolution, and highly sensitive optical imaging modality, which offers new insight into retinal structural changes in ocular disease, including retinal vascular occlusive diseases.<sup>4,6-8</sup> In patients with retinal artery occlusions, SD-OCT reveals increased thickness and reflectivity of the inner retinal layers (specifically the inner nuclear layer, inner plexiform layer and ganglion cell layer) and decreased reflectivity of the outer retinal layers, as the inner retina is edematous; prolonged ischemia results in subsequent atrophy of these layers.<sup>8-10</sup>

In this case report, we present a young patient with an isolated occlusion of a double branch cilioretinal artery, supplying main portions of the macula. Although the cilioretinal artery was patent with no filling delay in the FA, inner retinal edema followed by inner retinal atrophy identified on SD-OCT along the distribution of the cilioretinal artery was indicative of the previous occlusion of the cilioretinal artery. The boundaries of the cilioretinal artery distribution were sharply demarcated on SD-OCT both in terms of the initial edema and the subsequent atrophy.

## Conclusions

SD-OCT demonstrates the structural retinal changes that occur in the acute and subsequent phases of cilioretinal artery occlusion. SD-OCT is a valuable imaging modality which assists in the diagnosis of retinal vascular occlusion.

## References

1. Elasque L, Ballions JC, Labrouze JM, et al. Isolated occlusion of a cilioretinal artery. *J Fr Ophthalmol* 1999; 22: 388–93.
2. Elasri F, Souhail H, Reda K, et al. Isolated cilioretinal artery occlusion as an initial manifestation of polycythemia vera. *Middle East Afr J Ophthalmol* 2010; 17: 275–7.
3. Messner LV, Newman TL, Bartlett M, Conto JE. Cilioretinal artery occlusion with central retinal vein occlusion. *Optom Vis Sci.* 1999; 76: 741-6.
4. Brown GC, Moffat K, Cruess, A, et al. Cilioretinal artery obstruction. *Retina* 1983; 3: 182-7.
5. Shields MV, Welch RJ, Say EAT, et al. Cilioretinal artery imaged with optical coherence tomography angiography. *Ophthalmol* 2017; 124: 1448.
6. An L, Li P, Lan G, et al. High-resolution 1050 nm spectral domain retinal optical coherence tomography at 120 kHz A-scan rate with 6.1 mm imaging depth. *Biomed Opt Express.* 2013; 4: 245–59.
7. Leitgeb R., Hitzenberger C, Fercher A. Performance of Fourier domain vs. time domain optical coherence tomography. *Opt Express.* 2003; 11, 889–94.
8. Wolf-Schnurrbusch UE, Ghanem R, Rothenbuehler SP, et al. Predictors of short-term visual outcome after anti-VEGF therapy of macular edema due to central retinal vein occlusion. *Invest Ophthalmol Vis Sci.* 2011; 52: 3334-7.
9. Mańkowski W, Wylegała E. Optical coherence tomography (OCT) in central retinal occlusion with sparing cilioretinal artery--a case report. *Klin Oczna.* 2008; 110: 304-7.
10. Murthy RK, Grover S, Chalam KV. Sequential spectral domain OCT documentation of retinal changes after branch retinal artery occlusion. *Clin Ophthalmol.* 2010; 4: 327–9.

# Oncocytoma of the Lacrimal Duct: A Rare Tumor of Eyelid

Havva Serap Toru, MD<sup>1</sup>; Ebru Erol Uzunoglu, MD<sup>2</sup>; Cigdem Dicle Arican, MD<sup>2</sup>; Beyhan Demirhan<sup>3</sup>

<sup>1</sup> Akdeniz University School of Medicine, Department of Pathology, Antalya, Turkey

<sup>2</sup> Dr. Munif Islamoglu Government Hospital, Department of Pathology, Kastamonu, Turkey

<sup>3</sup> ClinLab Ankara Laboratory, Ankara/Turkey

## Abstract

This report demonstrates a rare case of lacrimal duct obstruction from a rare tumor. A 69 year-old otherwise healthy woman presented with a small nodular lesion in the plica semilunaris of left upper eyelid. Microscopic evaluation of the excised tumor revealed a oncocytoma.

## Introduction

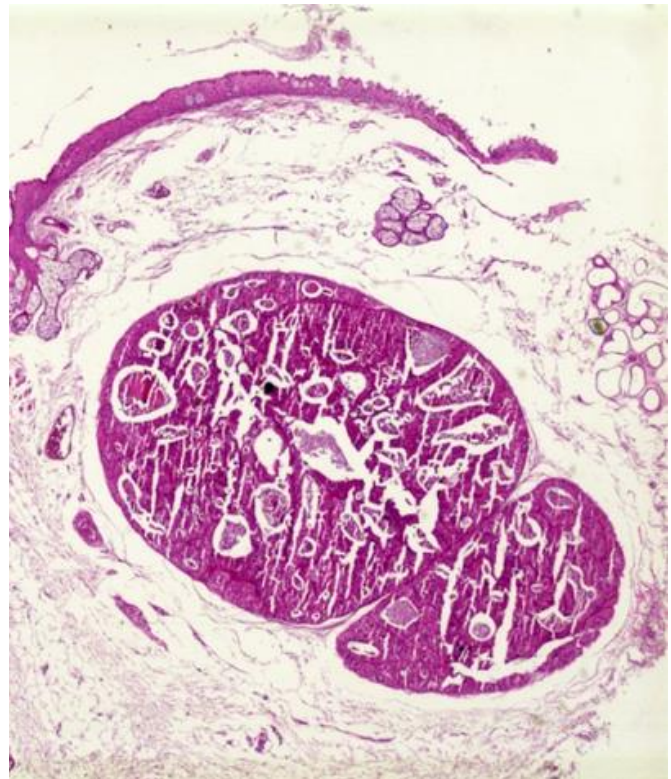
Most lacrimal duct obstruction is caused by chronic inflammation. Neoplastic lesions rarely cause lacrimal duct obstruction.<sup>1</sup> Tumors of lacrimal sac are rare and most of the tumors have an epithelial origin. Oncocytoma of lacrimal sac is exceedingly rare.<sup>2-4</sup> Oncocytomas are benign adenomatous tumors characterized by large, swollen eosinophilic cells with abundant mitochondria.<sup>5,6</sup>

In this report we present an occult oncocytoma of lacrimal duct in the upper eyelid, which is a very rare entity in ocular region.

## Case Report

During the routine physical examination of a 69 year-old systematically healthy woman, a small nodular lesion was detected in the plica semilunaris of left upper eye-lid. The patient was asymptomatic. The upper eyelid mass was 0.3 cm in diameter, pinkish and nodular. Light microscopic evaluation of

the excised lesion revealed what appeared to be two separate circumscribed nodular tumors, likely continuing in the same channel beneath the conjunctival epithelium (Figure 1). The tumor was



**Figure 1**

*H&E stained light microscopy of the tumor discloses what appears to be two separate tumors (20x magnification).*

### Correspondence:

Havva Serap Toru, MD  
Department of Pathology  
Akdeniz University School of Medicine  
07058 Antalya, Turkey  
Email: serap\_toru@yahoo.com

**Conflict of Interest:** The authors report no conflicts of interest.

**Contributions:** All authors contributed equally.

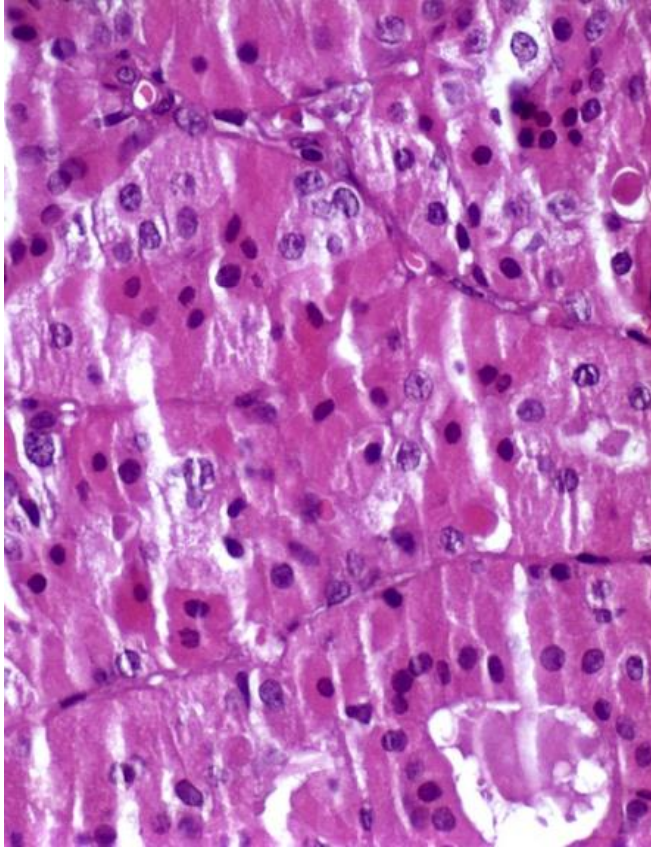
**Accepted for Publication:** February, 2018

This work is licensed under a Creative Commons Attribution Non-Commercial 3.0 License (CC BY-NC 3.0).

©Copyright Toru, et al., 2018.

Licensee Ophthosience Publishers, USA

composed of lobules and nodules which shows acinar features lined by oncocytic cells. The tumor cells had abundant, granular and eosinophilic cytoplasm and vesicular nuclei (Figure 2). Mitotic activity or



**Figure 2**  
*H&E stained light microscopy of the tumor discloses tumor cells with abundant, granular and eosinophilic cytoplasm and vesicular nuclei (400x magnification).*

vascular invasion was not seen. These findings are consistent with a diagnosis of oncocytoma.

## Discussion

Lacrimal duct obstruction usually manifests with epiphora.<sup>4</sup> In this case, the patient was asymptomatic, and the patient was only diagnosed after routine clinical examination. Often, lacrimal duct obstructions are caused by chronic inflammation, irradiation, dacryoliths, sarcoidosis, and other granulomatous processes.<sup>7</sup> The most common lacrimal duct tumor is a papilloma.

Neoplasms are rare and mostly epithelial nature. In the epithelium, oncocytoma of lacrimal sac is exceedingly rare.<sup>8</sup>

The benign tumors of the lacrimal duct include squamous papilloma, transitional papilloma, fibrous histiocytoma, oncocytoma, and hemangiopericytoma, in order of frequency. The malignant tumors of the lacrimal duct include squamous cell carcinoma, lymphoma, melanoma, transitional carcinoma, mucoepidermoid carcinoma, and adenocarcinoma, in order of frequency. The most serious malignancies of the lacrimal sac are malignant melanoma and transitional cell carcinoma where the latter is associated with a 100% mortality rate.<sup>9</sup>

An accurate diagnosis and clinical follow-up is very important. The biggest challenge in this region is the difficulty of total resection and recurrence of both malignant and benign tumors.

Oncocytomas are benign epithelial tumors growing in a glandular pattern. The most common location of oncocytomas is the salivary glands; they may also be found in the thyroid, parathyroid, pituitary, and adrenal glands. The kidney is the one of the well-known locations for oncocytomas. Initially, oncocytes were noted in lacrimal glands in necropsy series of Böck and Schlagenhauß in 1938 and first oncocytoma case of ocular adnexa was reported by Radnot in 1941.<sup>5</sup>

Early diagnosis of the tumor when it is small makes total excision easier. In these cases, canalicular progression of the tumor may occur and should be excluded. Benign oncocytomas can recur or transform into malignant oncocytoma.<sup>10</sup>

## Conclusion

Although oncocytomas rarely occur in the ocular region, oncocytomas should be kept in differential diagnosis in cases of dacryocystitis or lacrimal duct obstruction.

## References

1. Pe'er J, Hidayat AA, Ilsar M, et al. Glandular tumors of the lacrimal sac. Their histopathologic patterns and

- possible origins. *Ophthalmol.* 1996; 103: 1601-5.
2. Domanski H, Ljungberg O, Andersson LO, Schele B. Oxyphil cell adenoma (oncocytoma) of the lacrimal sac. Review of the literature. *Acta Ophthalmol (Copenh)*. 1994; 72: 393-6.
  3. O'Connor SR, Tan JH, Walewska R, et al. Angiotropic lymphoma occurring in a lacrimal sac oncocytoma. *J Clin Pathol.* 2002; 55: 787-8.
  4. Mulay K, Nair A, Honavar SG. Occult oncocytoma of the lacrimal sac. *Saudi J Ophthalmol.* 2014; 28:76-8.
  5. Thaller VT, Collin JR, McCartney AC. Oncocytoma of the eyelid: a case report. *Br J Ophthalmol.* 1987; 71: 753-6.
  6. Al-Mohtaseb Z, Lee S, Yen MT. Oncocytoma of the upper conjunctival fornix. *Eye Reports* 2011; 1: 17-9.
  7. Anderson NG, Wojno TH, Grossniklaus HE. Clinicopathologic findings from lacrimal sac biopsy specimens obtained during dacryocystorhinostomy. *Ophthal Plast Reconstr Surg.* 2003; 19: 173-6.
  8. Stefanyszyn MA, Hidayat AA, Pe'er JJ, Flanagan JC. Lacrimal sac tumors. *Ophthal Plast Reconstr Surg.* 1994; 10: 169-84.
  9. Ni C, D'Amico DJ, Fan CQ, Kuo PK. Tumors of the lacrimal sac: a clinicopathological analysis of 82 cases. *Int Ophthalmol Clin.* 1982; 22: 121-40.
  10. Heathcote JG, Kumalo TG, Willis NR, Mills DM. Oncocytoma of the lacrimal caruncle. *Can J Ophthalmol.* 1986; 21:178-83.



# Technique to reduce failure with corneal stromal tattoo in patients with symptomatic laser peripheral iridotomy

Emma C. Davies, MD; Haijirah N. Saeed, MD; Roberto Pineda II, MD

Cornea and Refractive Surgery Service, Massachusetts Eye and Ear Infirmary, Harvard Medical School

---

## Abstract

**Purpose.** This study presents two cases of persistent glare symptoms after laser peripheral iridotomy despite the patients undergoing corneal stromal tattooing with black ink placed in a manually constructed stromal pocket. Possible reasons as to why each case resulted in treatment failure are described along with a technique to reduce such failures.

**Methods.** The study design is a retrospective report of two cases of corneal stromal tattooing after symptomatic laser peripheral iridotomy.

**Results.** In both cases, failure to resolve glare symptoms was attributed to patchy pigmentation in the corneal stromal pocket that was highlighted only with retro-illumination at the slit lamp.

**Conclusions.** The method proposed to reduce failures is verifying with retro-illumination for defects in a corneal tattoo as a method to reduce failures.

---

## Introduction

The history of corneal tattooing dates back to 150 AD when Roman physician and philosopher, Galen of Pergamum, first described a method of cauterizing the corneal surface with a heated stilet and then staining with gallnut and copper sulfate to treat opacities of the

eye.<sup>1</sup> After Galen's reference to corneal tattooing, the practice is not mentioned until 1869 when oculoplastic surgeon Louis Von Weckner introduced a new method. He inserted black ink, India ink, or China ink into the cornea via a grooved needle to create a "pupil" in leukomatous corneas.<sup>2</sup> Despite its ancient history, cornea tattooing is still used to this day for cosmesis of corneal scars and for symptomatic reduction of glare in patients with aniridia, albinism, large colobomas, and peripheral iridotomies.<sup>3</sup>

There are several different tattooing methods that exist, with variations on pigmentation delivery and type of pigment used. Pigmentation may be placed either by multiple stromal micropunctures or by creating a stromal pocket, either created manually or assisted by femtosecond laser, to contain the pigment.<sup>4</sup> Many different types of pigmentation exist and are classified into two broad categories, the chemical method and non-metallic dyes. The chemical method uses a metallic substance, most commonly platinum and gold chloride, to trigger a chemical reaction to precipitate pigmentation in the cornea.<sup>5</sup> Non-metallic dyes, such as India ink, Chinese ink, lamp black, organic dyes, and uveal pigment from animal eyes, are used to color the cornea directly.<sup>5</sup> Pigmentation with the chemical method is considered easier and more efficient but tends to fade faster, particularly with

### Correspondence:

Emma C. Davies, MD  
Massachusetts Eye and Ear Infirmary  
Harvard University  
Boston, MA  
E-mail: emma\_davies@meei.harvard.edu  
Phone: (617) 573-4393

**Conflict of Interest:** The authors report no conflicts of interest.

**Contributions:** All authors contributed equally.

**Accepted for Publication:** May, 2018

This work is licensed under a Creative Commons Attribution Non-Commercial 3.0 License (CC BY-NC 3.0).

©Copyright Davies et al., 2018.

Licensee Ophthosience Publishers, USA

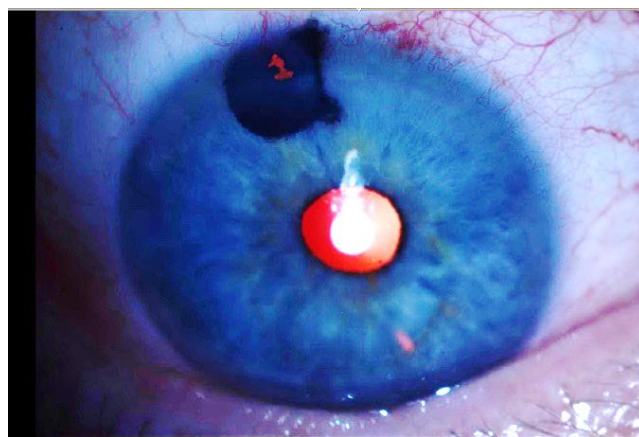
microstromal puncture, than pigmentation with non-metallic dyes.<sup>5</sup>

## Case Reports

The corneal tattooing technique utilized in the current case reports of patients with a peripheral iridotomy complicated by glare is detailed below. After the eye is prepped and draped in the usual sterile ophthalmic fashion, the eye is anesthetized with lidocaine gel and a lid speculum is placed to obtain adequate exposure. A peripheral corneal stromal pocket is made using a crescent blade overlying the region of the iris defect. Several drops of sterile black ink (Black dye #1, Huck Spalding, NY) are placed in the stromal pocket using a large bore IV cannula (20 gauge) and the ink is smoothed across the pocket with the cannula tip to achieve, ideally, uniform coverage. The stromal pocket is closed, and the eye is irrigated copiously with balanced salt solution. The patient is then escorted to a slit lamp where retro-illumination through the pupil is used to determine any residual light penetration through the stromal tattoo. If retro-illumination demonstrates defects in the pigmentation, additional placement of dye in the corneal stromal pocket is performed for complete obscuration of the defect.

The first case is a 55-year-old woman who presented to clinic with complaints of severe, debilitating glare after a superotemporal laser peripheral iridotomy for narrow angle. She underwent keratopigmentation using black dye within a manual stromal pocket in the right eye. She noticed immediately after the procedure that she still had reduced but persistent glare. Despite a seemingly opaque corneal stromal tattoo on direct visualization, retro-illumination demonstrated areas with persistent light transmission due to patchy pigmentation coverage. She underwent a repeat corneal stromal tattoo procedure with brown dye. Immediate examination with retro-illumination at the time of the procedure demonstrated that the repeat corneal tattoo allowed no penetration of light. She reported complete resolution of her symptoms immediately afterwards as well as at her one-week follow-up.

The second case is a 60-year-old gentleman who presented with reports of glare and streaks of light after placement of a laser peripheral iridotomy in superior iris of the right eye in the setting of narrow angle glaucoma. On examination, he had a trans-illumination defect. He underwent corneal stromal tattooing over the superior iridotomy in the right eye with black ink placed in a manual stromal pocket. At follow-up, he reported persistent glare symptoms and retro-illumination highlighted regions within the corneal stromal tattoo where pigmentation was patchy and light transmittance remained visible. He underwent repeat corneal stromal tattooing in order to fully cover the region in the superior periphery with black dye. At one week post-procedure, he reported improvement in his symptoms but still noticed slight glare. Retro-illumination at this time demonstrated a persistent area of incomplete blockage of light in the superior periphery as well as a smaller area in the inferonasal midperiphery (Figure 1). The patient elected to undergo pupilloplasty (without revision of his inferonasal trans-illumination defect) with complete resolution of his symptoms after surgical repair of the iridectomy (symptoms continued to be resolved one month after surgical repair).



**Figure 1**  
*Slit lamp biomicroscopy of the patient's right eye after repeat corneal stromal tattoo with black ink, demonstrating a mostly opaque tattoo in the superior periphery with a region of persistent shine-through upon retro-illumination, and an unrelated inferonasal midperipheral trans-illumination defect.*

## Discussion

Corneal tattooing has been demonstrated to be effective in reducing complaints of photic phenomena such as halos, glare, and ghost images in patients with a peripheral laser iridotomy.<sup>6-8</sup> However, corneal tattooing may fail to resolve symptoms. In this report, we highlight one potential cause for this failure by presenting two cases of persistent symptoms of glare from a peripheral laser iridotomy site after undergoing corneal stromal tattooing. The reason for these failures is believed to be inadequate coverage of the corneal stromal pocket with ink despite a seemingly opaque tattoo. Only after retro-illumination was utilized, were we able to highlight defects in the tattoo and to confirm adequate coverage after repeat keratopigmentation.

We propose applying retro-illumination during corneal tattooing as a method to reduce failure rate. If retro-illumination demonstrates defects in the pigmentation, we propose additional placement of dye in the corneal stromal pocket for complete obscuration of the defect. The use of retro-illumination immediately after the corneal tattooing procedure may further guide placement of pigmentation and enhance success rates of this method.

## References

1. Roy N. Tattooing of the cornea. *Can Med Assoc J* 1938; 39: 436-8.
2. Islam N, Franks W. Therapeutic corneal tattoo following peripheral iridotomy complication. *Eye* 2006; 20: 389-90.
3. Garrido-Hermosilla A, Angeles-Figueroa R, Gessa-Sorroche M. Surgical intrastromal keratopigmentation using tattoo ink. *Arch Soc Esp Oftalmol* 2014; 89: 286-9.
4. Burris T, Holmes-Higgin D, Silvestrini T. Lamellar intrastromal corneal tattoo for treating iris defects (artificial iris). *Cornea* 1998; 17: 169-73.
5. Miller G, Gupta N, Howarth D, et al. A tale of two corneal tattoos. *Can J Ophthalmol* 2009; 44: 470-2.
6. Alio J, Rodriguez A, Toffaha B. Keratopigmentation (corneal tattooing) for the management of visual disabilities of the eye related to iris defects. *Br J Ophthalmol* 2011; 95: 1397-1401.
7. Faschinger C. Corneal tattoo with dysphotopsia after iridotomy: worth a chance! *Spektrum Augenheilkd* 2015; 29: 118-22.
8. Ricardo J, Medhi J, Pineda R. Femtosecond laser-assisted keratopigmentation for the management of visual disabilities due to peripheral iridectomies. *J Glaucoma* 2015; 24: e22-4.

# Brown syndrome associated with Marcus-Gunn jaw winking ptosis

Ilaria Biagini, CO; Alba Miele, MD; Gianni Virgili, MD; Stanislao Rizzo, MD

Neuromusculoskeletal Department, Eye Clinic, University of Florence, Florence, Italy

## Abstract

Brown syndrome is a rare mechanical disorder characterized by restriction of the superior oblique trochlea-tendon complex. Marcus-Gunn jaw winking ptosis is a more common congenital oculofacial synkinesis in which blepharoptosis is associated with upper eyelid contraction that accompanies jaw movement. In this report, we present the case of a 50-year-old woman with unilateral Brown syndrome and Marcus-Gunn jaw winking ptosis in the fellow eye.

## Introduction

Brown Syndrome, first reported in 1950, is a rare mechanical disorder characterized by restriction of the superior oblique trochlea-tendon complex; it may be congenital or acquired, secondary to trauma or inflammation. Clinical signs, which may be constant or intermittent, include deficiency of elevation in adduction, and in moderate to severe disease, downshoot of the eye occurs in adduction. The vast majority of cases, approximately 90%, are unilateral.<sup>1</sup>

Marcus-Gunn jaw winking ptosis, also known as the jaw-winking phenomenon or Marcus-Gunn Syndrome, first reported in 1883, is a more common congenital oculofacial synkinesis in which blepharoptosis is associated with upper eyelid contraction that accompanies jaw movement. As with Brown Syndrome, the vast majority of cases of Marcus-

Gunn jaw winking ptosis are unilateral.

Approximately one-half of all cases of Marcus-Gunn are associated with strabismus: superior rectus palsy in one-quarter of cases and a double elevator palsy on another one-quarter of cases.<sup>2-4</sup>

## Case Report

A 50-year-old woman with a history of Brown Syndrome, without any current visual complaints, presented for routine strabismus evaluation. The patient was diagnosed with Brown Syndrome in her right eye at age 7, when she was found to have active and passive restriction of elevation in adduction in the right eye, with divergence in upgaze, downshoot in adduction, and hypotropia in primary position with a compensatory chin elevation. Her family history is unknown. At age 20, she underwent surgical recession of superior oblique tendon of the right eye, twice.

Now, at age 50, on examination, her visual acuity was 20/30 and 20/25 in the right and left eyes, respectively, with -2.50 Diopter spherical correction in each eye. External examination demonstrated a head tilt to the left; she had mild blepharoptosis of the left upper eyelid. Hirschberg corneal reflex testing demonstrated 18 prism diopters of extotropia and 12 prism diopters of right hypotropia with left eye fixation, at distance, and 20 prism diopters of extotropia and 6 prism diopters of right hypotropia with left eye fixation, at near. The unilateral cover test

### Correspondence:

Ilaria Biagini, CO  
Neuromusculoskeletal Department, Eye Clinic  
University of Florence  
Florence, Italy  
E-mail: [ilaria.biagini55@gmail.com](mailto:ilaria.biagini55@gmail.com)  
Phone: 39-339-60529

**Conflict of Interest:** The authors report no conflicts of interest.

**Contributions:** All authors contributed equally.

**Accepted for Publication:** May, 2018

This work is licensed under a Creative Commons Attribution Non-Commercial 3.0 License (CC BY-NC 3.0).

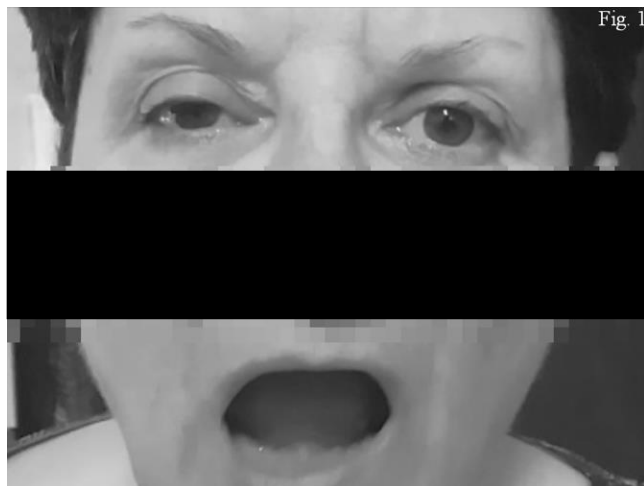©Copyright Biagini et al., 2018.

Licensee Ophthalmoscience Publishers, USA



demonstrated the capacity of the patient to maintain fixation with the right eye, confirming her ability to alternate fixation with both eyes. Prism cover testing confirmed 18 prism diopters of extotopia and 12 prism diopters of right hypotropia with left eye fixation, at distance, though 30 prism diopters of extotopia and 10 prism diopters of right hypotropia with left eye fixation, at near. Worth four dot testing revealed alternating suppression, although fixation was mostly observed with the left eye. During the red filter test, the patient complained of transitory diplopia only at the moment of the switch of the fixing eye. Extraocular motility testing demonstrated a mild downshoot of the right eye in adduction, with bilateral medial rectus hypofunction. Ipsilateral superior oblique hyperfunction was absent.

During the orthoptic examination, left upper eyelid contraction was incidentally observed while the patient was speaking. A directed evaluation was then performed: the patient to open her mouth, and upon doing so, the left upper eyelid retracted concurrently by approximately 3 mm (Figure 1). When her mouth was closed, the left eyelid returned to its normal position (Figure 2). The patient made note that she had been experiencing this peculiar phenomenon for many years, but she had never complained about it as she was not bothered by the eyelid retraction.

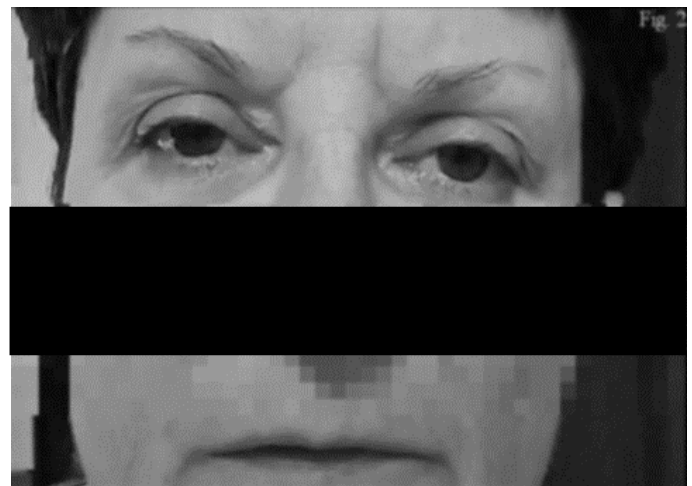

**Figure 1**  
Approximately 3 mm of left upper eyelid retraction is present when the patient's mouth is open.

## Discussion

Brown Syndrome and Marcus-Gunn jaw winking ptosis are rare ocular conditions. Brown Syndrome is the result of restriction of passage of the superior oblique muscle tendon and sheath through the pulley-like trochlea.<sup>1</sup> While it may be secondary to trauma or inflammation, it is often congenital, as in this case. The Marcus-Gunn jaw winking ptosis is the result of aberrant nerve connections, specifically a co-innervation between the elevator palpebrae superior muscle from the oculomotor nucleus and external pterygoid portion of the trigeminal nucleus.<sup>2,5</sup> The Marcus-Gunn jaw winking ptosis may also be acquired in rare cases, but is most often congenital. In this case, it is uncertain whether the patient's condition was acquired or congenital.

A high incidence of strabismus and amblyopia have been associated with the Marcus-Gunn jaw winking ptosis.<sup>5</sup> Amblyopia has been reported in just over one-half (59%) of cases, and strabismus in approximately one-half of cases: superior rectus palsy in one-quarter of cases and a double elevator palsy on another one-quarter of cases.<sup>2-6</sup> Other ocular associations have been reported in rare cases, such as synergistic divergence<sup>7</sup> and Duane's retraction syndrome.<sup>8</sup> This case presented is rare, as we are aware



**Figure 2**  
Upon closing her mouth, the left upper eyelid retraction resolves and the eyelid returns to its normal position.

of only two other cases of Brown Syndrome associated with Marcus-Gunn jaw winking ptosis reported in the referenced medical literature: Szetter, et al. in 1968<sup>9</sup> and Artifoni, et al. in 1965.<sup>10</sup>

---

## References

1. Wilson ME, Eustis HS Jr, Parks MM. Brown's syndrome. *Surv Ophthalmol*. 1989; 34(3): 153-72.
2. Gunn RM. Congenital ptosis with peculiar associated movements of the affected lid. *Trans Ophthal Soc UK*. 1883; 3: 283-7.
3. Disorders of the eyelids. In: Kanski JJ, ed. *Clinical Ophthalmology*, 3rd ed. Butterworth-Heinemann Medical; 1997, p. 1-26.
4. Torres MR, Calixto N Jr, Oliveira LR, et al. Marcus-Gunn Phenomenon: differential diagnosis of palpebral ptoses in children. *J Pediatr (Rio J)*. 2004 May-Jun;80(3):249-52.
5. Sundareswaran S, Nipun CA, Kumar V. Jaw - winking phenomenon: Report of a case with review of literature. *Indian J Dent Res*. 2015; 26(3): 320-3.
6. Pratt SP, Beyer CK, Johnson CC. The Marcus-Gunn phenomenon. *Ophthalmology*. 1984; 91: 27-30.
7. Brodsky MC, Pollock SC, Buckley EG. Neural misdirection in congenital ocular fibrosis syndrome: implications and pathogenesis. *J Pediatr Ophthalmol Strabismus*. 1989; 26(4): 159-61.
8. Isenberg S, Blechman B. Marcus-Gunn jaw winking and Duane's retraction syndrome. *J Pediatr Ophthalmol Strabismus*. 1983; 20(6): 235-7.
9. Szetter K, Wójtowicz S. An atypical case of unilateral Brown's syndrome with coexisting abortive Marcus-Gunn synkinetic movements. *Klin Oczna*. 1968; 38(2): 405-9.
10. Artifoni E, Bertoncini G. On a rare familial association of the Brown syndrome with the Marcus-Gunn phenomenon. *Ann Ottalmol Clin Ocul*. 1965; 91(7): 563-76.

# An atypical presentation of pseudoxanthoma elasticum (PXE) without angioid streaks or peau d'orange

Choi Mun Chan, MBBS<sup>1</sup>; Amer Omar, MD<sup>2</sup>; Maria Pefkianaki, MD, PhD<sup>2</sup>; Ranjan Rajedram, MD<sup>2</sup>; David Paige, MBBS<sup>3</sup>; Rino Cerio, FRCP<sup>3</sup>; Michel Michaelides, MBBS, MD<sup>2</sup>

<sup>1</sup> Singapore National Eye Centre, Singapore

<sup>2</sup> Moorfields Eye Hospital, National Health Service Foundation Trust, London, UK

<sup>3</sup> The Royal Hospital London, National Health Service Foundation Trust, London, UK

## Abstract

Pseudoxanthoma Elasticum (PXE) is an inherited multi-system disorder with potentially fatal complications. Biallelic mutations in the *ABCC6* gene, which encodes an ATP-binding cassette transporter, have been identified to underlie this disease. Patients with pseudoxanthoma elasticum (PXE) classically have angioid streaks and peau d'orange. In this report, we present the case of a 9-year-old girl with histologically confirmed PXE, who did not have either angioid streaks or peau d'orange in either eye. Her only ophthalmic finding was the presence of bilateral optic disc drusen. This atypical presentation of PXE highlights that the presence of optic disc drusen in the absence of other signs should alert the physician to consider PXE.

## Introduction

Pseudoxanthoma Elasticum (PXE), also known as Gronblad-Stranberg syndrome, is a genetically inherited multi-system disorder with potentially fatal complications. Biallelic mutations in the ATP-binding cassette sub-family C member 6 (*ABCC6*) gene, which encodes an intracellular transporter protein, multidrug

resistance-associated protein 6 (MRP6), have been identified to underlie this disease, though the mechanism by which these mutations result in pathology remains unknown. Progressive accumulation of calcium and other minerals in the elastic fibers of connective tissue, particularly within the skin, blood vessels, and retina, results in pathology. In the retina, damage to the elastic layers of Bruch's membrane (the thin 2 to 4 micron thick acellular layer, which consists of the basement membrane of the retinal pigment epithelial cell layer of the eye, between the retina and the choroid) results in linear breaks in Bruch's membrane, known as angioid streaks. Diffuse partially confluent deposition of calcium and other minerals at the level of Bruch's membrane results in the peau d'orange appearance of the retina.<sup>1,2</sup> Angioid streaks and peau d'orange are readily visible on ophthalmoscopy and retinal autofluorescence imaging may assist in the diagnosis by demonstrating stippled autofluorescence typical of peau d'orange and hypoauflorescent fissures typical of angioid streaks.<sup>3</sup>

## Case Report

An asymptomatic 9-year-old girl was referred to

### Correspondence:

Choi Mun Chan, MBBS  
Singapore National Eye Centre  
11 Third Hospital Avenue  
Singapore 168751  
E-mail: chan.choi.mun@sneec.com.sg  
Phone: (65) 6322-8330

**Conflict of Interest:** The authors report no conflicts of interest.

**Contributions:** All authors contributed equally.

**Accepted for Publication:** May, 2018

This work is licensed under a Creative Commons Attribution Non-Commercial 3.0 License (CC BY-NC 3.0).

©Copyright Chan et al., 2018.

Licensee Ophthosience Publishers, USA

a tertiary ophthalmological institution for evaluation of possible papilledema. On examination, her best-corrected visual acuity was 20/20 in each eye, with 0.75 Diopter spherical correction in each eye. Visual fields were full and color vision was normal.

Dilated fundus examination revealed bilateral full optic discs with irregular, elevated and hyperemic neuroretinal rims, more so in the right eye than the left. Both retinae had a predominantly confluent yellow appearance, which was centered on the posterior pole and extended to the mid-periphery, sparing the peri-papillary area (Figure 1). Angioid streaks were absent.

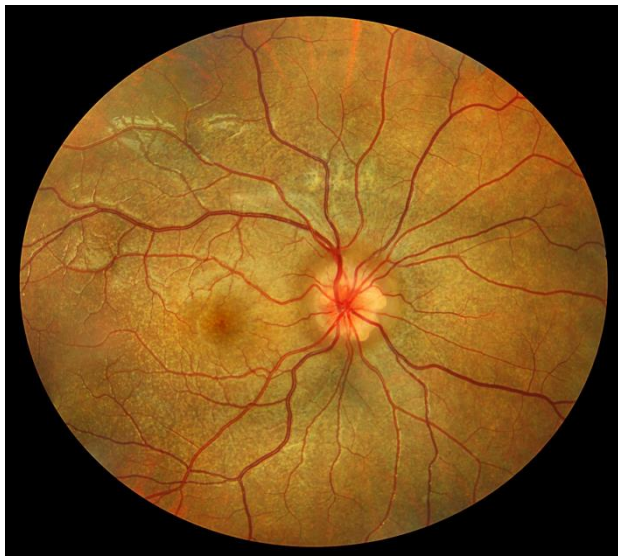B-scan ultrasonography demonstrated small hyperechoic lesions over the optic nerve heads, consistent with optic disc drusen. Fundus autofluorescence imaging confirmed the diagnosis of optic disc drusen which appeared hyperautofluorescent (Figure 2), though revealed the absence of the stippled autofluorescence typical of peau d'orange and the hypoautofluorescent fissures typical of angioid streaks. Macular spectral-domain

optical coherence tomography revealed intact retinal architecture. Electrophysiological testing showed normal symmetrical photopic, scotopic and macular responses.

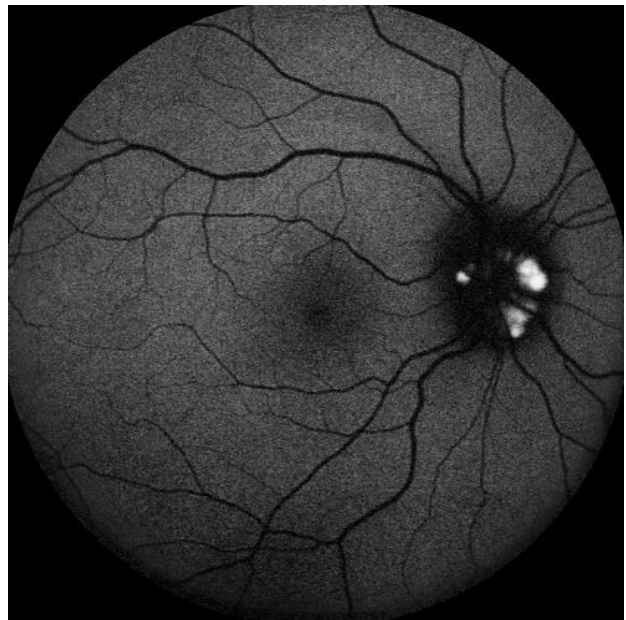
Dermatological assessment revealed tiny yellowish papules on the neck and a solitary axillary café-au-lait lesion. Biopsy of a papule established the diagnosis of PXE; histology demonstrated degeneration of the elastic fibers within the dermis (Figure 3) with evidence of calcium deposition on Von Kossa stains (Figure 4).

## Discussion

PXE should be considered in the differential diagnosis of bilateral optic disc drusen, even in the absence of angioid streaks and peau d'orange. Optic nerve head drusen appear to occur more frequently in PXE patients, with a reported prevalence of 6% to 20%, compared to 0.3% in the general population.<sup>4,5</sup> It has

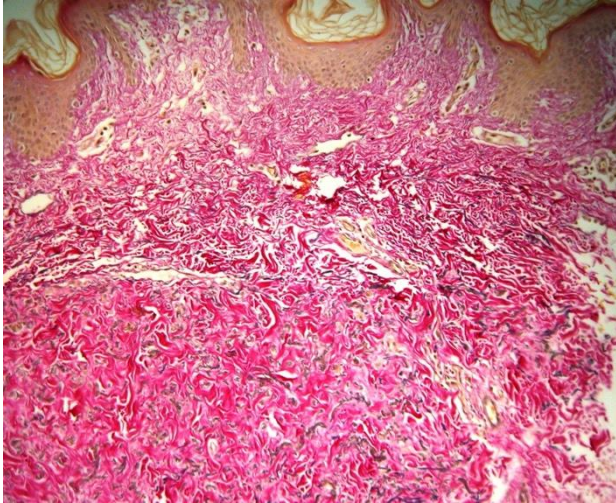


**Figure 1**  
*Fundus photograph demonstrated a full optic nerve head with irregular elevation and hyperemia, as well as a predominantly confluent yellow appearance of the posterior pole, without peau d'orange.*

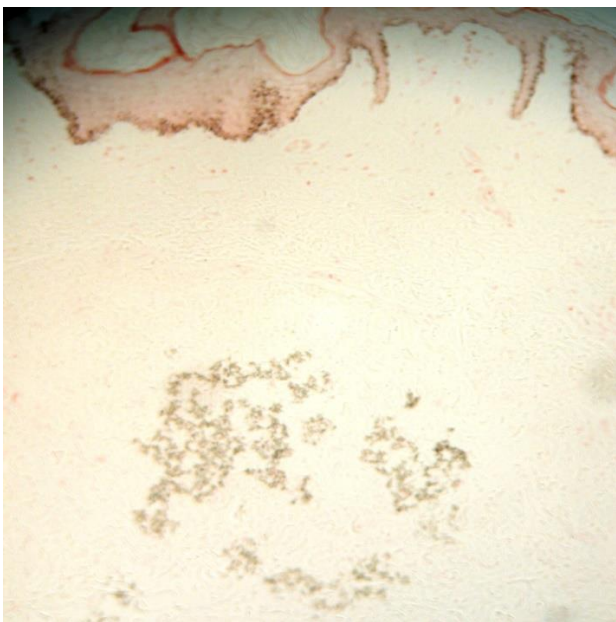


**Figure 2**  
*Retinal autofluorescence imaging demonstrated hyperautofluorescent optic drusen. There is no stippled autofluorescence typical of peau d'orange and no hypoautofluorescent fissures typical of angioid streaks.*





**Figure 3**  
Hematoxylin and eosin staining of a skin papule demonstrated degeneration of the elastic fibers within the dermis.



**Figure 4**  
Von Kossa staining of a skin papule demonstrated calcium deposition.

been postulated the increased frequency may be due to calcification or increased rigidity of the lamina cribrosa.<sup>4</sup>

As this case demonstrates, angioid streaks and peau d'orange may not be present in PXE. It is

noteworthy that these features are rare in children and not consistent among adults. The predominantly confluent yellow appearance of this patient's retinae, which was centered on the posterior pole and extended to the mid-periphery, is consistent with confluent deposition of calcium and other minerals at the level of Bruch's membrane, and has been observed in cases of PXE. However, the peau d'orange appearance of the retina results from the subconfluent, or partially confluent, deposition of calcium and other minerals that surrounds the more central confluent deposition.<sup>1,2</sup> This young patient did not have this subconfluent deposition surrounding the confluent deposition, and thus did not have the peau d'orange appearance of the retina.

This atypical presentation of PXE highlights that the presence of optic disc drusen in the absence of other signs should alert the physician to consider PXE. It is important not to miss a diagnosis of PXE as this is an inherited multi-system disorder with potentially fatal complications. Timely diagnosis is critical to initiate screening for the associated cardiac and gastrointestinal manifestations and to act upon them accordingly.

## References

1. Gliem M, Zaeytijd JD, Finger RP, et al. An update on the ocular phenotype in patients with pseudoxanthoma elasticum. *Front Genet* 2013; 4:14, 1-13.
2. Spaide RF. Peau d'orange and angioid streaks: Manifestations of Bruch membrane pathology. *Retina* 2015; 35: 392-7.
3. Sawa M, Ober MD, Freund KB, Spaide RF. Fundus autofluorescence in patients with pseudoxanthoma elasticum. *Ophthalmology* 2006; 113(5): 814-20.
4. Finger RP, Charbel Issa P, Ladewig M, et al. Fundus autofluorescence in pseudoxanthoma elasticum. *Retina* 2009; 29(10): 1496-505.
5. Pierro L, Brancato R, Minicucci M, Pece A. Echographic diagnosis of drusen of the optic nerve head in patients with angioid streaks. *Ophthalmologica* 1994; 208(5): 239-42.