

Bilateral reversible visual loss secondary to undiagnosed acute porphyria in a child

Wendy Yen Nee See, MD^{1,2}; Chua Lausanne, MBBS^{1,2}

¹ Department of Ophthalmology, Faculty of Medicine, University of Malaya, Kuala Lumpur, Malaysia

² Department of Ophthalmology, Hospital Umum Sarawak, Sarawak, Malaysia

Abstract

The porphyrias are a group of disorders, often genetic, characterized by systemic or localized accumulation of porphyrins, precursors of the iron metalloprotein heme. Acute porphyria is a descriptive category of the porphyrias in which patients present with sudden onset neurologic symptoms or attacks of pain. Ocular and visual manifestations of porphyria are rare. In this case report, a 9-year-old girl, with no past medical history, experienced bilateral visual loss. She was diagnosed with acute porphyria with autonomic dysfunction, including neuropathic abdominal pain, peripheral neuropathy, seizure, and labile hypertension. After seizure control and blood pressure regulation, the patient was treated with intravenous dextrose and a high carbohydrate diet, and her vision loss recovered to a visual acuity of 20/40 bilaterally.

Introduction

Acute porphyria is difficult to diagnose due to its nonspecific and wide spectrum of clinical manifestations.¹ Porphyria is rare but potentially life-threatening.²⁻⁴ It is a type of inborn error of metabolism, characterized by the deficiency of rate-limiting enzyme 5-aminolevulinic acid synthase in the

heme biosynthesis pathway.^{3,5} The eight types of porphyria are broadly classified into hepatic or erythropoietic porphyria, based on their primary site of porphyrin precursors overproduction. In this case report, a 9-year-old girl, with no past medical history, presented with bilateral visual loss.

Case Report

A 9-year old girl, with no past medical history, was admitted for acute gastroenteritis after a four-day history of fever, abdominal pain, diarrhea, and vomiting. On admission, she developed acute urinary and bowel incontinence, and, subsequently, limb weakness with a throbbing headache. On the third day of admission, she complained of bilateral sudden painless loss of vision.

This was her first episode of such occurrence. The mother claimed that the child was healthy with no known medical illness before this admission. She had no known drug or food allergies as well. There was no family history of familial neurological disorder.

Bedside physical examination revealed a lethargic child with peripheral neuropathy. Visual acuity was counting fingers in each eye. Pupils were 6 mm dilated in each eye and sluggish to light reflex, with no

Correspondence:

Wendy Yen Nee See, MD
Eye Department, Hospital Umum Sarawak
A1-4, The Arcadia, Jalen Stampin Timur
93350 Kuching, Sarawak, Malaysia
E-mail: wendy_choc@hotmail.com
Phone: (60) 1-28863662

Conflict of Interest: The authors report no conflicts of interest.

Contributions: All authors contributed equally.

Accepted for Publication: March 2, 2020

This work is licensed under a Creative Commons Attribution Non-Commercial 3.0 License (CC BY-NC 3.0).

©Copyright See et al., 2020.

Licensee Ophthosience Publishers, USA

relative afferent pupillary defect. No ophthalmoplegia or ptosis noted. Fundi were normal with no optic disc swelling. Intraocular pressures were within normal range.

With a provisional diagnosis of meningitis and atypical bilateral retrobulbar optic neuritis, she completed intravenous ceftriaxone and subsequently started on systemic steroids in accordance with the Optic Neuritis Treatment Trial. An extensive investigative workup was performed to exclude infectious, demyelinating, and autoimmune connective tissue causes. However, all results were unremarkable. Specifically, serum and cerebrospinal fluid oligoclonal band and aquaporin-4 were negative. Echocardiogram, abdominal X-ray, ultrasound of abdomen and neck, and carotid Dopplers were normal. A non-contrasted computed tomography (CT) brain was normal. Magnetic resonance imaging (MRI) of the brain (Figure 1) showed nonspecific signals in the splenium corpus callosum. There was no meningeal enhancement of the optic nerves (Figure 2). MRI of the spine showed no abnormalities.

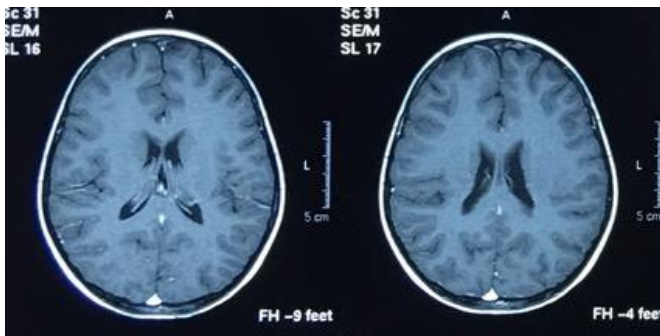


Figure 1
Magnetic resonance imaging of the brain revealed nonspecific signals in the splenium corpus callosum.

Although her symptoms and vision did not improve, she was discharged with a psychiatric referral. Following discharge, she developed a seizure episode at home.

She was readmitted to the hospital, and the pediatrician prescribed phenytoin for seizure control. Repeat neuroimaging revealed bilateral parieto-

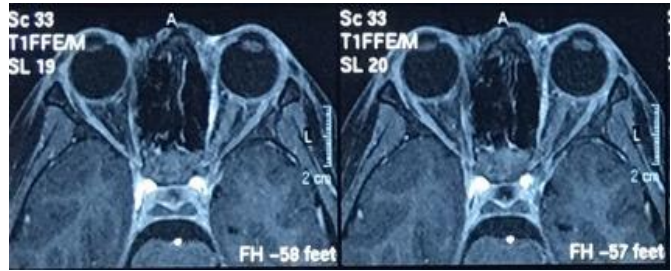


Figure 2
Magnetic resonance imaging of the optic nerves revealed no meningeal enhancement of the optic nerves.

occipital white matter hypodensities (Figure 3) with no hydrocephalus. Another series of blood, urine, and cerebrospinal fluid evaluations were performed to investigate for an inborn error of metabolism and autoimmune encephalitis mosaic workup, which were all unremarkable. Nevertheless, suspecting autoimmune encephalitis, she completed a course of intravenous immunoglobulin, without resolution of her signs and symptoms.

Subsequently, she developed hypertensive crisis requiring intravenous labetalol and later developed steroid-induced glaucoma requiring topical

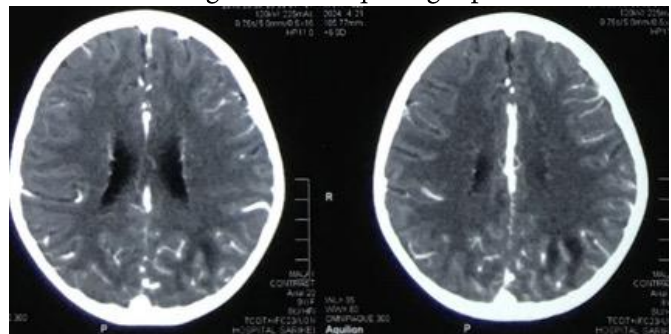


Figure 3
Repeat neuroimaging revealed bilateral parietooccipital white matter hypodensities with no hydrocephalus.

anti-glaucoma treatment. Her unrelenting abdominal pain persisted despite frequent morphine.

With no appropriate diagnosis, an incidental finding of dark-colored urine raised the suspicion of acute porphyria. However, a total of three samples of urinary porphobilinogen and delta-aminolevulinic acid ALA revealed normal results. Nevertheless, the

constellation of signs and symptoms were suggestive of acute porphyria.

The patient responded well to treatment for acute porphyria: intravenous 10% dextrose and high carbohydrate diet. Her phenytoin (which was porphyrinogenic) was stopped. Oral clonidine was added to treat her autonomic dysfunction. By the third day of treatment, her pain score reduced, and she no longer required morphine. Six months later, the child was doing well on a regular high sugar diet. She was no longer on antihypertensive drugs or anti-glaucoma medications. Pupils reactions returned to normal and fundoscopic examination remained normal with no optic disc swelling. Her visual acuities improved to 20/40 bilaterally.

Discussion

Ocular involvement in porphyria is exceedingly rare and usually consists of inflammatory scleritis or ocular surface disease as a result of porphyrin precursors in secreted tears inciting ocular surface inflammatory responses.⁶ Acute bilateral visual loss in a porphyric child has been reported though is exceedingly unusual.^{1,7,8}

Our patient presented with various autonomic manifestations of porphyria. Firstly, neuropathic abdominal pain, followed by periphery neuropathy, seizure, and labile hypertension.

Several hypotheses have been postulated to explain the visual loss in acute porphyria: the loss of autonomic regulation in the vertebrobasilar system causing reversible cerebral vasospasm in parieto-occipital areas,⁷ and hypertensive encephalopathy or direct neurotoxicity due to accumulation of heme precursors.¹

Posterior reversible encephalopathy syndrome (PRES) is linked to functional vascular changes too.^{8,9} The typical PRES neuroimaging pattern is bilateral white matter abnormalities in the parieto-occipital areas, seen in the MRI in our case. Roth and Ferbert reported that the CT scan tends to miss 50% of these

findings.⁸ Unlike the posterior circulation ischemic event, PRES is reversible as the name suggested. A generalized seizure can occur in PRES.^{8,9} However, treatment with anti-seizure medications (known to be porphyrinogenic) formed a vicious cycle in our patient.

Misinterpreting symptoms of acute porphyria in pre-pubertal children is common.¹⁰ The diagnosis of porphyria is typically identified by the high urinary level of ALA and porphobilinogen.^{1,4} Hultdin, et al. redefined age- and gender-corrected basal reference values for urinary ALA and porphobilinogen in children. Furthermore, they noted that the levels can remain “normal” in juvenile acute porphyria patients, even during an acute intermittent porphyria attack,¹⁰ presumably the case in our patient.

Management involves the termination of an acute attack, symptomatic relief, and avoiding precipitants.² Intravenous heme is the treatment of choice.^{2,4,5} Increased carbohydrate intake can resolve mild attacks by inhibiting delta-ALA synthetase.^{2,5} In refractory cases, liver transplant had been suggested.² Supportive treatment for hypertension, electrolyte imbalance, and pain control should also be addressed accordingly.⁵

This case emphasizes the importance awareness of the occurrence of visual loss in acute porphyria. Physicians should have a high index of suspicion in cases of visual loss in a child with unexplained abdominal pain. Appropriate and timely diagnosis and management in these patients is essential.

References

1. Bhuyan S, Sharma AK, Sureka RK, et al. Sudden bilateral reversible vision loss: a rare presentation of acute intermittent porphyria. *The Journal of the Association of Physicians of India* 2014; 62(5):432-4.
2. Khadilkar SV, Yadav RS, Patel BA. *Porphyrias*. In: Khadilkar SV, et al., editors. *Neuromuscular Disorders*. Singapore: Springer Nature 2018:493-502.
3. Balwani M, Desnick RJ. The porphyrias: advances in diagnostic and treatment. *Blood* 2012; 120(23):4496-504.

4. Cappellini MD, Brancaleoni V, Graziadei G, et al. Porphyrias at a glance: diagnosis and treatment. *Internal and Emergency Medicine* 2010; 5(1): 73-80.
5. Anderson KE, Bloomer JR, Bonkovsky HL, et al. Recommendations for the diagnosis and treatment of the acute porphyrias. *Annals of Internal Medicine* 2005; 142(6): 439-50.
6. Sati A, Sangwan VS, Basu S. Porphyria: varied ocular manifestations and management. *BMJ Case Reports* 2013; 22: 1-4.
7. Kupferschmidt H, Bont A, Schnorf H, et al. Transient cortical blindness and bioccipital brain lesions in two patients with acute intermittent porphyria. *Annals of Internal Medicine* 1995; 123(8): 598-600.
8. Zheng X, Liu X, Wang Y, et al. Acute intermittent porphyria presenting with seizures and posterior reversible encephalopathy syndrome: two case reports and a literature review. *Medicine (Baltimore)* 2018; 97(36): 1-8.
9. Roth C, Ferbert A. The posterior reversible encephalopathy syndrome: what's certain, what's new? *Practical Neurology* 2011; 11(3):136-44.
10. Hultdin J, Schmauch A, Wikberg A, et al. Acute intermittent porphyria in childhood: a population-based study. *Acta Paediatrica* 2003; 92(5): 562-8.