

# Nd:YAG laser hyaloidotomy in a case of Valsalva retinopathy with premacular hemorrhage

Mete Güler, MD<sup>1</sup>, Özlem Güler, MD<sup>2</sup>, Burak Bilgin, MD<sup>3</sup>

<sup>1</sup>Department of Ophthalmology, Adıyaman University, School of Medicine, Adıyaman, Turkey.

<sup>2</sup>Department of Emergency Medicine, Adıyaman University Education and Research Hospital, Adıyaman, Turkey.

<sup>3</sup>Department of Ophthalmology, Adıyaman University Education and Research Hospital, Adıyaman, Turkey.

## Abstract

Intraretinal, preretinal, and vitreous hemorrhages in Valsalva retinopathy result from retinal capillary rupture following sudden increased retinal venous pressure from a rise in intrathoracic or intraabdominal pressure. While preretinal hemorrhages may resolve on their own or may be treated with vitrectomy, we report a case of Valsalva retinopathy with a dense premacular hemorrhage which was successfully treated with Nd:YAG laser hyaloidotomy. A healthy 27-years-old man presented with sudden painless visual loss after heavy cement bag lifting. His visual acuity was count fingers in the affected eye. A dilated fundus examination revealed a large dome shaped preretinal hemorrhage. Nd:YAG laser hyaloidotomy was performed at the inferotemporal margin of the preretinal hemorrhage. Within two weeks, the visual acuity improved to 20/20 and there was near complete resolution of the preretinal hemorrhage. Non-visually-significant pigment epithelial injury was noted at the site of the laser application. Nd:YAG laser hyaloidotomy may be a safe and effective therapeutic option in select patients with Valsalva retinopathy with preretinal hemorrhage.

## Introduction

The Valsalva maneuver entails forcible exhalation against a closed glottis and produces a sudden increase in the venous blood pressure from a rise in intrathoracic or intraabdominal pressure.<sup>1</sup> This pressure rise causes a decompensation at the levels of the retinal capillary bed resulting in either unilateral or bilateral retinal hemorrhages. These retinal hemorrhages are usually found below the internal limiting membrane, but can occasionally break through to become a preretinal (subhyaloid) or vitreous hemorrhage.<sup>2</sup> The preretinal hemorrhages are often premacular, limiting visual acuity. Valsalva retinopathy is relatively rare and often self-limited event, but premacular hemorrhages may take several months to clear.<sup>3</sup> We report a case of Valsalva retinopathy with a dense premacular hemorrhage which was successfully treated with neodymium yttrium aluminum garnet (Nd:YAG) laser hyaloidotomy.

## Case Report

A healthy 27-year-old man who works in the construction industry was referred to our clinic after

### Correspondence:

Mete Güler, MD  
Department of Ophthalmology  
Adıyaman University School of Medicine  
02040 Adıyaman, Turkey  
Email: meteglr@yahoo.com  
Phone: +90 04162233800  
Fax: +90 04162231690

**Conflict of Interest:** The authors report no conflicts of interest.

**Contributions:** All authors contributed equally.

**Accepted for Publication:** April 1, 2014

This work is licensed under a Creative Commons Attribution Non-Commercial 3.0 License (CC BY-NC 3.0).

©Copyright Jimenez et al., 2014.

Licensee Ophthosience Publishers, USA

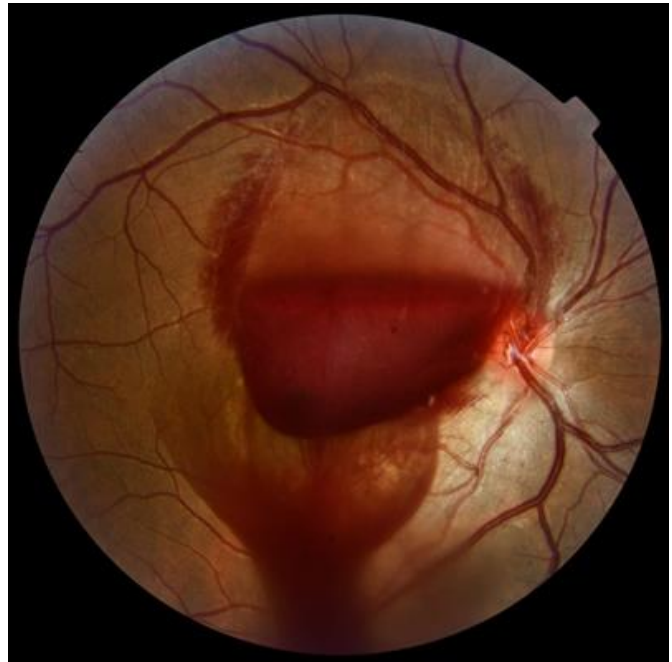initially presenting to the department of emergency medicine with sudden painless visual loss after lifting a heavy cement bag. His visual acuity was counting fingers and 20/20 with best correction in the right and left eyes, respectively. Anterior segment examination was unremarkable, and intraocular pressures were within normal in both eyes. A dilated fundus examination revealed a large dome shaped preretinal hemorrhage in the right eye and a normal fundus in the left eye. We initially decided to observe the evolution of the hemorrhage over a period of one week, and no substantial changes were observed during this period.

After informed consent was obtained, an Nd:YAG laser (Selecta Duet Laser System, Lumenis, Tokyo, Japan) posterior hyaloidotomy was performed with Volk SuperQuad 160 (Volk Optical, Inc., Mentor, Ohio, USA) fundus laser lens. Four shots of the Nd:YAG laser were applied to the inferotemporal margin of the preretinal hemorrhage. The laser power was set initially to 1.2 mJ and gradually was increased to 5.4 mJ. Just after the last shot, which produced a successful hyaloidotomy, the hemorrhage rapidly drained into the vitreous cavity (Figure 1).

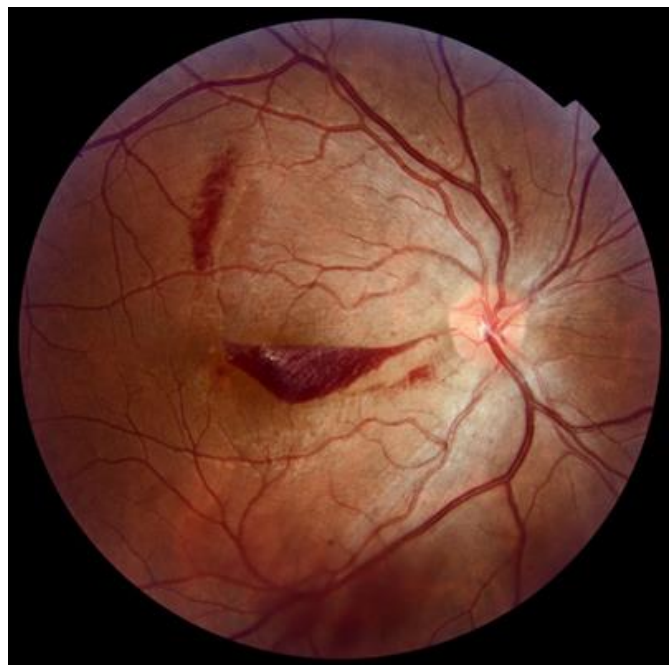Within one week of the laser hyaloidotomy, visual acuity improved to 20/50 with a dramatic decrease in the preretinal hemorrhage (Figure 2). By two weeks following the procedure, visual acuity improved to 20/20 near complete resolution of the preretinal hemorrhage (Figure 3). However, fluorescein angiography revealed a window defect located just temporal to the fovea (Figure 4).

## Discussion

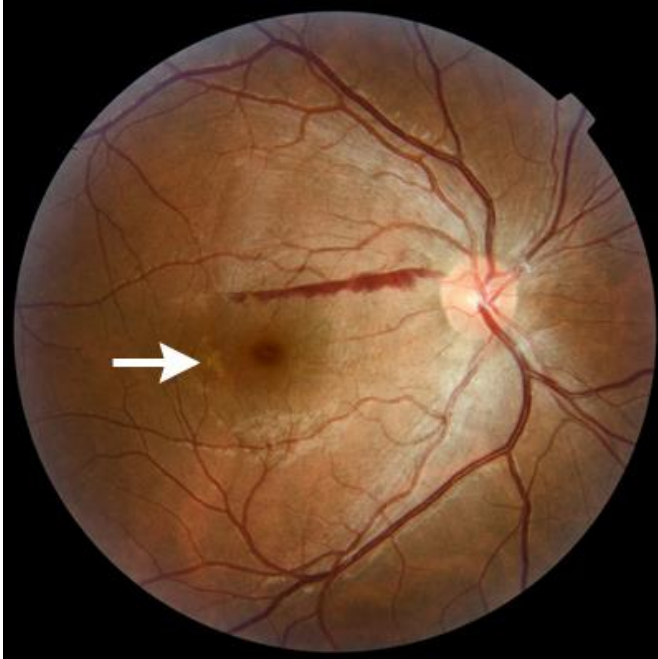
Patients with Valsalva retinopathy often give a history of recent heavy lifting, straining, vomiting, coughing, or the labor of childbirth.<sup>3,4</sup> With rupture of a retinal capillary or capillaries following the increased venous pressure, intraretinal, preretinal, and vitreous hemorrhages may occur. In younger patients with an intact posterior hyaloid, the preretinal hemorrhage becomes encapsulated in the



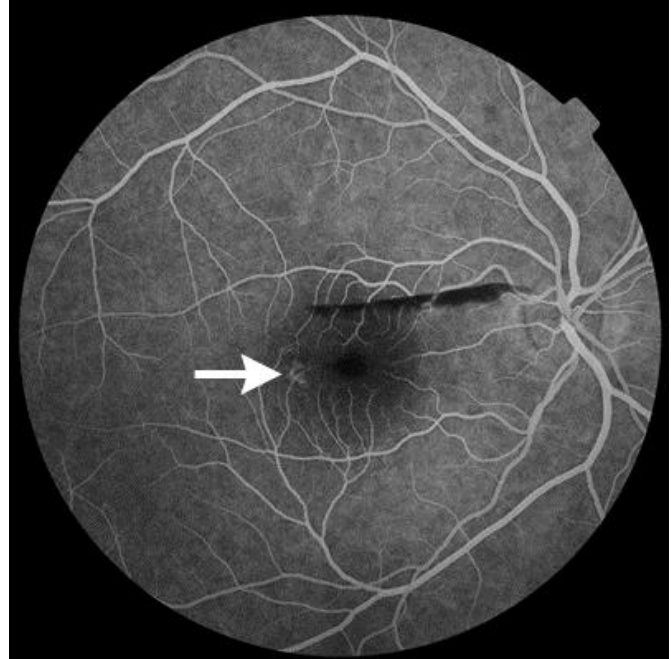
**Figure 1**  
*Drainage of preretinal hemorrhage into the vitreous cavity is seen in the right eye within moments following the Nd-YAG laser hyaloidotomy.*



**Figure 2**  
*One week after the laser hyaloidotomy, a small amount of preretinal hemorrhage remains in front of the macula. There is also dispersed vitreous hemorrhage inferiorly.*



**Figure 3**  
By two weeks after the laser hyaloidotomy, only a slight amount preretinal hemorrhage remains in a non-visually-significant location in front of the superior macula. There is some depigmentation (arrow) of the retinal pigment epithelium (RPE) temporal to the fovea, where the laser was applied.



**Figure 4**  
Mid-phase fluorescein angiography, performed two weeks after the laser procedure, shows a window defect (arrow) located temporal to the fovea where the laser was applied.

subhyaloid space. Similar preretinal hemorrhages may be found in cases of retinal neovascularization such as from diabetic retinopathy, as well as in hemorrhagic posterior vitreous detachment (with or without retinal breaks), rupture of a retinal macroaneurysm, blunt ocular trauma, hypertensive retinopathy, Terson syndrome of vitreous hemorrhage with subarachnoid hemorrhage, other causes of elevated intracranial pressure, and shaken baby syndrome.

Preretinal hemorrhages in Valsalva retinopathy are often premacular and visually-significant. Preretinal hemorrhages of less than one disk diameter often tend to resolve spontaneously in a short period of time and a conservative approach of observation is generally justifiable. By contrast, the spontaneous resolution of large and dense hemorrhages is often unlikely or may be prolonged.<sup>5</sup> However, prolonged contact of the retina with hemoglobin and its by-products may

cause toxic retinal damage, which may be irreversible, resulting in permanent visual sequelae.<sup>6,7</sup>

Various techniques have been used to treat premacular hemorrhage. The hemorrhage may be displaced using intravitreal injection of an expansile gas with or without recombinant tissue plasminogen activator for hemolysis. The hemorrhage may be removed with a pars plana vitrectomy. The hemorrhage may be drained into the vitreous cavity with laser hyaloidotomy.<sup>5</sup>

Nd-YAG laser hyaloidotomy is relatively non-invasive procedure and easy to perform. The goal of the laser hyaloidotomy is to create an opening in the posterior hyaloid where the preretinal hemorrhage has become encapsulated in the subhyaloid space, allowing the hemorrhage to drain out of the subhyaloid space and into the vitreous cavity. It has been reported to be safe and effective in a select group of patients with Valsalva retinopathy.<sup>1</sup> Patients with a premacular subhyaloid hemorrhage larger than 3 disc diameters with no longer than 3 weeks duration may

be considered as candidates for Nd:YAG laser treatment.<sup>8</sup> The timing of Nd:YAG laser procedure is important issue. When the premacular blood is coagulated, drainage with YAG laser may not be possible. It has been observed that hemorrhage of longer 3 weeks duration do not drain despite visible posterior hyaloid punctures at the surface of the premacular blood.<sup>9</sup>

Complications of Nd:YAG laser hyaloidotomy include iatrogenic damage to the retina or RPE, development of a macular hole, creation of a persistent premacular cavity, retinal detachment, and epiretinal membrane formation.<sup>10,11</sup> The power settings of the Nd:YAG laser systems used for this procedure often must be relatively high to achieve the goal of creating a hyaloidotomy.<sup>12,13</sup> However, the proximity of the laser treatment site to the retinal surface poses a risk of photomechanical retinal injury.<sup>5</sup> It has been suggested that energy levels should be below 9mJ,<sup>8</sup> though energy levels even below that amount may result in iatrogenic retinal injury. In our patient, there was RPE injury temporal to the fovea.

Therefore it is essential to ensure that the aiming beam is focused precisely on the surface of the premacular subhyaloid hemorrhage, rather than behind the surface closer to the retina; in addition, it has been recommended that the treating surgeon select a hyaloidotomy site where there is a sufficient thickness of preretinal blood that may protect the underlying retina.<sup>1</sup> Furthermore, the site of the hyaloidotomy should be at a location close to the inferior edge of the preretinal hemorrhage to provide gravitational drainage, but distant from the fovea and the retinal blood vessels to avoid foveal or retinovascular injury.<sup>1</sup> Nevertheless, when performed appropriately, Nd:YAG laser hyaloidotomy may be a safe and effective therapeutic option for Valsalva retinopathy.

## References

1. Durukan AH, Kerimoglu H, Erdurman C, et al. Long-term results of Nd:YAG laser treatment for premacular subhyaloid haemorrhage owing to Valsalva retinopathy. *Eye (Lond)* 2008; 22:214-8.
2. Tildsley J, Srinivasan S. Valsalva retinopathy. *Postgrad Med J* 2009;85:110.
3. El-Defrawy H, Sallam A, McKechnie CJ, et al. Valsalva retinopathy in pregnancy. Should we treat? *JRSM Short Rep* 2011; 2:45.
4. Chapman-Davies A, Lazarevic A. Valsalva maculopathy. *Clin Exp Optom* 2002; 85:42-5.
5. García Fernández M, Navarro JC, Castaño CG. Long-term evolution of Valsalva retinopathy: a case series. *J Med Case Rep* 2012; 6:346.
6. De Maeyer K, Van Ginderdeuren R, Postelmans L, et al. Sub-inner limiting membrane haemorrhage: causes and treatment with vitrectomy. *Br J Ophthalmol* 2007; 91:869-72.
7. Khan MT, Saeed MU, Shehzad MS, et al. Nd:YAG laser treatment for Valsalva premacular hemorrhages: 6 month follow up: alternative management options for preretinal premacular hemorrhages in Valsalva retinopathy. *Int Ophthalmol* 2008; 28:325-7.
8. Ulbig MW, Mangouritsas G, Rothbacher HH, et al. Long-term results after drainage of premacular subhyaloid hemorrhage into the vitreous with a pulsed Nd:YAG laser. *Arch Ophthalmol* 1998; 116:1465-9.
9. Cheung CM, Benson MT. Post-chemotherapy premacular subhyaloid haemorrhage. *Eye (Lond)* 2003; 17:97-9.
10. Goel N, Kumar V, Seth A, et al. Spectral-domain optical coherence tomography following Nd:YAG laser membranotomy in valsalva retinopathy. *Ophthalmic Surg Lasers Imaging* 2011; 42:222-8.
11. Kwok AK, Lai TY, Chan NR. Epiretinal membrane formation with internal limiting membrane wrinkling after Nd:YAG laser membranotomy in valsalva retinopathy. *Am J Ophthalmol* 2003; 136:763-6.

12. Raymond LA. Neodymium:YAG laser treatment for hemorrhages under the internal limiting membrane and posterior hyaloid face in the macula. *Ophthalmology* 1995; 102:406-11.
13. Venkatesh R, Manoj S, Badella S, et al. Rapid resolution of premacular haemorrhage after Nd:YAG laser posterior hyaloidotomy. *Acta Ophthalmol Scand* 2007; 85:216-7.