

# Oncocytoma of the Lacrimal Duct: A Rare Tumor of Eyelid

Havva Serap Toru, MD<sup>1</sup>; Ebru Erol Uzunoglu, MD<sup>2</sup>; Cigdem Dicle Arican, MD<sup>2</sup>; Beyhan Demirhan<sup>3</sup>

<sup>1</sup> Akdeniz University School of Medicine, Department of Pathology, Antalya, Turkey

<sup>2</sup> Dr. Munif Islamoglu Government Hospital, Department of Pathology, Kastamonu, Turkey

<sup>3</sup> ClinLab Ankara Laboratory, Ankara/Turkey

## Abstract

This report demonstrates a rare case of lacrimal duct obstruction from a rare tumor. A 69 year-old otherwise healthy woman presented with a small nodular lesion in the plica semilunaris of left upper eyelid. Microscopic evaluation of the excised tumor revealed a oncocytoma.

## Introduction

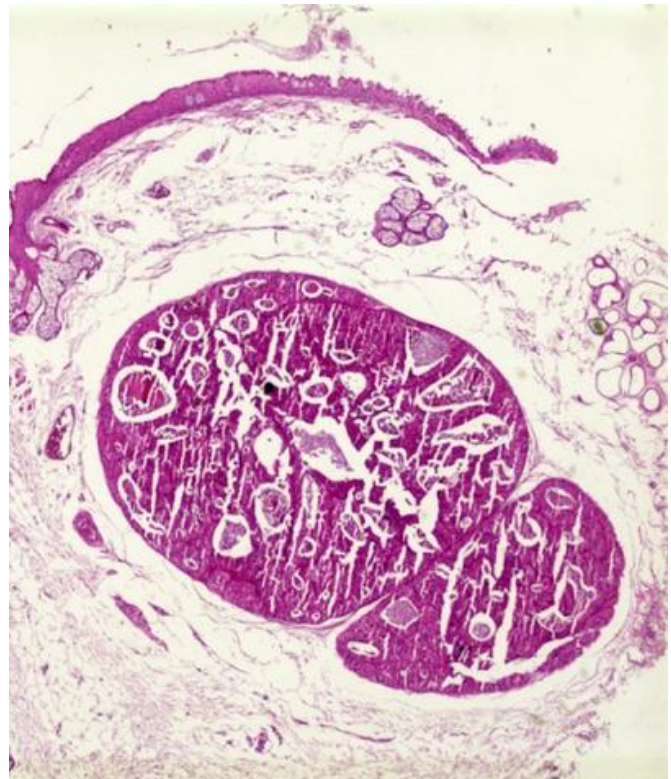Most lacrimal duct obstruction is caused by chronic inflammation. Neoplastic lesions rarely cause lacrimal duct obstruction.<sup>1</sup> Tumors of lacrimal sac are rare and most of the tumors have an epithelial origin. Oncocytoma of lacrimal sac is exceedingly rare.<sup>2-4</sup> Oncocytomas are benign adenomatous tumors characterized by large, swollen eosinophilic cells with abundant mitochondria.<sup>5,6</sup>

In this report we present an occult oncocytoma of lacrimal duct in the upper eyelid, which is a very rare entity in ocular region.

## Case Report

During the routine physical examination of a 69 year-old systematically healthy woman, a small nodular lesion was detected in the plica semilunaris of left upper eye-lid. The patient was asymptomatic. The upper eyelid mass was 0.3 cm in diameter, pinkish and nodular. Light microscopic evaluation of

the excised lesion revealed what appeared to be two separate circumscribed nodular tumors, likely continuing in the same channel beneath the conjunctival epithelium (Figure 1). The tumor was



**Figure 1**

*H&E stained light microscopy of the tumor discloses what appears to be two separate tumors (20x magnification).*

### Correspondence:

Havva Serap Toru, MD  
Department of Pathology  
Akdeniz University School of Medicine  
07058 Antalya, Turkey  
Email: serap\_toru@yahoo.com

**Conflict of Interest:** The authors report no conflicts of interest.

**Contributions:** All authors contributed equally.

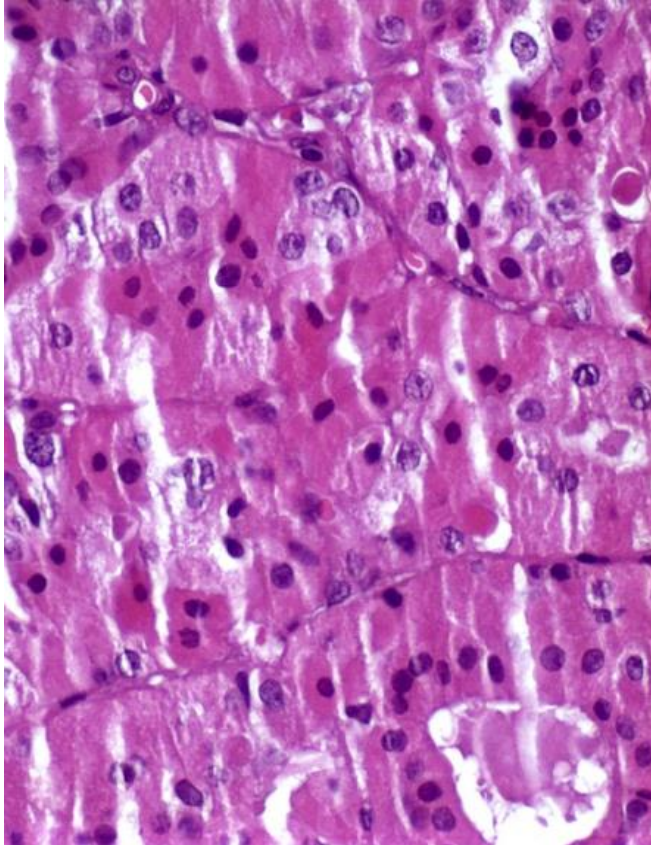
**Accepted for Publication:** February, 2018

This work is licensed under a Creative Commons Attribution Non-Commercial 3.0 License (CC BY-NC 3.0).

©Copyright Toru, et al., 2018.

Licensee Ophthosience Publishers, USA

composed of lobules and nodules which shows acinar features lined by oncocytic cells. The tumor cells had abundant, granular and eosinophilic cytoplasm and vesicular nuclei (Figure 2). Mitotic activity or



**Figure 2**  
*H&E stained light microscopy of the tumor discloses tumor cells with abundant, granular and eosinophilic cytoplasm and vesicular nuclei (400x magnification).*

vascular invasion was not seen. These findings are consistent with a diagnosis of oncocytoma.

## Discussion

Lacrimal duct obstruction usually manifests with epiphora.<sup>4</sup> In this case, the patient was asymptomatic, and the patient was only diagnosed after routine clinical examination. Often, lacrimal duct obstructions are caused by chronic inflammation, irradiation, dacryoliths, sarcoidosis, and other granulomatous processes.<sup>7</sup> The most common lacrimal duct tumor is a papilloma.

Neoplasms are rare and mostly epithelial nature. In the epithelium, oncocytoma of lacrimal sac is exceedingly rare.<sup>8</sup>

The benign tumors of the lacrimal duct include squamous papilloma, transitional papilloma, fibrous histiocytoma, oncocytoma, and hemangiopericytoma, in order of frequency. The malignant tumors of the lacrimal duct include squamous cell carcinoma, lymphoma, melanoma, transitional carcinoma, mucoepidermoid carcinoma, and adenocarcinoma, in order of frequency. The most serious malignancies of the lacrimal sac are malignant melanoma and transitional cell carcinoma where the latter is associated with a 100% mortality rate.<sup>9</sup>

An accurate diagnosis and clinical follow-up is very important. The biggest challenge in this region is the difficulty of total resection and recurrence of both malignant and benign tumors.

Oncocytomas are benign epithelial tumors growing in a glandular pattern. The most common location of oncocytomas is the salivary glands; they may also be found in the thyroid, parathyroid, pituitary, and adrenal glands. The kidney is the one of the well-known locations for oncocytomas. Initially, oncocytes were noted in lacrimal glands in necropsy series of Böck and Schlagenhauß in 1938 and first oncocytoma case of ocular adnexa was reported by Radnot in 1941.<sup>5</sup>

Early diagnosis of the tumor when it is small makes total excision easier. In these cases, canalicular progression of the tumor may occur and should be excluded. Benign oncocytomas can recur or transform into malignant oncocytoma.<sup>10</sup>

## Conclusion

Although oncocytomas rarely occur in the ocular region, oncocytomas should be kept in differential diagnosis in cases of dacryocystitis or lacrimal duct obstruction.

## References

1. Pe'er J, Hidayat AA, Ilsar M, et al. Glandular tumors of the lacrimal sac. Their histopathologic patterns and

- possible origins. *Ophthalmol.* 1996; 103: 1601-5.
2. Domanski H, Ljungberg O, Andersson LO, Schele B. Oxyphil cell adenoma (oncocytoma) of the lacrimal sac. Review of the literature. *Acta Ophthalmol (Copenh)*. 1994; 72: 393-6.
  3. O'Connor SR, Tan JH, Walewska R, et al. Angiotropic lymphoma occurring in a lacrimal sac oncocytoma. *J Clin Pathol.* 2002; 55: 787-8.
  4. Mulay K, Nair A, Honavar SG. Occult oncocytoma of the lacrimal sac. *Saudi J Ophthalmol.* 2014; 28:76-8.
  5. Thaller VT, Collin JR, McCartney AC. Oncocytoma of the eyelid: a case report. *Br J Ophthalmol.* 1987; 71: 753-6.
  6. Al-Mohtaseb Z, Lee S, Yen MT. Oncocytoma of the upper conjunctival fornix. *Eye Reports* 2011; 1: 17-9.
  7. Anderson NG, Wojno TH, Grossniklaus HE. Clinicopathologic findings from lacrimal sac biopsy specimens obtained during dacryocystorhinostomy. *Ophthal Plast Reconstr Surg.* 2003; 19: 173-6.
  8. Stefanyszyn MA, Hidayat AA, Pe'er JJ, Flanagan JC. Lacrimal sac tumors. *Ophthal Plast Reconstr Surg.* 1994; 10: 169-84.
  9. Ni C, D'Amico DJ, Fan CQ, Kuo PK. Tumors of the lacrimal sac: a clinicopathological analysis of 82 cases. *Int Ophthalmol Clin.* 1982; 22: 121-40.
  10. Heathcote JG, Kumalo TG, Willis NR, Mills DM. Oncocytoma of the lacrimal caruncle. *Can J Ophthalmol.* 1986; 21:178-83.