

# Correlation of the cholesterol-to-high-density-lipoprotein Castelli risk index-1 with the choroidal and retinal nerve fiber layer thickness in patients with diabetes mellitus without retinopathy

Zeynep Eylül Ercan, MD, FEBO

Department of Ophthalmology, Hitit University Corum Education and Training Hospital, Corum, Turkey

## Abstract

**Purpose:** To determine the choroidal thickness and retinal nerve layer (RNFL) thickness changes in patients with diabetes mellitus (DM) without retinopathy in relation to their glycated hemoglobin (HbA1c) and Castelli risk index-1 (CRI-1) levels.

**Method:** This study examined the right eyes of 340 subjects. CRI-1 was calculated as the total cholesterol divided by high-density lipoprotein cholesterol. Five groups of 68 eyes were defined as follows: Group 1, control group consisting of healthy subjects; Group 2, DM patients with HbA1c from 7% to 9%; Group 3, DM patients with HbA1c from 7% to 9% and CRI-1 greater than 4; Group 4, DM patients with HbA1c greater than 9.1%; and, Group 5, DM patients with HbA1c greater than 9.1% and with CRI-1 greater than 4. Optical coherence tomography (OCT) measurements were taken using enhanced depth imaging. Choroidal thickness (CT) and RNFL thickness were compared within groups.

**Results:** CT was found to be lower in all DM groups compared with healthy subjects. In all nasal areas, CT was significantly thinner in group 5 than group 4. RNFL loss was only seen in the inferior temporal quadrant of all DM patients compared with the control group. There was no statistically significant difference between subgroups in RNFL measurements.

**Conclusion:** CRI-1, which is a marker of combined dyslipidemia abnormalities, is in use to predict atherosclerotic changes in DM patients. This study determined the CRI-1 also correlates with the CT of diabetic eyes but not the RNFL, and it can be used as an additional criterion in ophthalmological follow-ups of diabetic patients.

## Introduction

Diabetes mellitus (DM) is a common disease with major complications, one of which is diabetic retinopathy (DR). An increase in glycation end-product accumulation and inflammatory cytokine and adhesion factors results in retinal ischemia, which is thought to be the pathogenic mechanism underlying ocular disease.<sup>1</sup> The Diabetes Control and Complications Trial reported that approximately 11% of the total risk for diabetic retinopathy can be explained by glycemic exposure, and the remaining 89% of risk is thought to be generated by other factors.<sup>2</sup> Glycated hemoglobin (HbA1c) levels is a method for monitoring anti-hyperglycemic therapy which is directly related to the amount of plasma glucose.<sup>3</sup> Lower HbA1c levels have been shown to be associated with the magnitude of vision improvement following treatment.<sup>4</sup>

**Correspondence:**  
Zeynep Eylül Ercan  
Ophthalmology Department  
Hitit University  
Corum, Turkey  
Email: eylulercan@doctor.com  
Phone: + 90 532 205 9636

**Conflict of Interest:** The authors report no conflicts of interest.  
**Contributions:** All authors contributed equally.

**Accepted for Publication:** October, 2020  
This work is licensed under a Creative Commons Attribution Non-Commercial 3.0 License (CC BY-NC 3.0).  
©Copyright Ercan, et al., 2020.  
License Ophthoscience Publishers, USA

Choroidal circulation pathologies observed in DM, such as choriocapillaris obstruction, increased tortuosity, and narrowing of the choroidal vessels, also play a role in DR.<sup>5</sup> Even with good glycemic control with low HbA1c levels, capillary dropouts were seen in healthy looking retinas.<sup>6</sup> Due to its high blood flow, choroid is a potential site for atherosclerotic changes to occur. These changes may include an increase in thickness, a build-up of lipids at the suprachoroid and hypertrophy of the endothelial and vascular smooth muscle cells.<sup>7</sup> It has been shown in animal models that the atherosclerotic changes occur in the presence of hypercholesterolemia.<sup>8</sup> Studies involving different serum lipid types and levels have identified both negative and positive correlations between lipid levels and diabetic retinopathy.<sup>9,10</sup>

The total cholesterol to high-density lipoprotein cholesterol ratio (TC:HDL-C), known as the atherogenic or Castelli risk index-1 (CRI-1), is an indicator of vascular pathology risk and is commonly used to interpret microvascular disease risks in diabetic patients.<sup>11</sup> Patients with high CRI-1 have greater cardiovascular risk, possibly due to a higher atherogenic component (which is reported as the numerator), lower anti-atherosclerotic traits (denominator), or both.<sup>12</sup> Montgomery, *et al.* found that increases in total cholesterol and triglycerides cause deficits in inner retina functions.<sup>13</sup> Zhang, *et al.* also found that retinal function in hyperlipidemia patients was diminished, even prior to pathological changes in the fundus.<sup>14</sup> Therefore, we postulated that CRI-1 can be considered as a surrogate for microvascular disease risk in our subjects.

Optical coherence tomography (OCT) is a non-invasive technique commonly used for diabetic retinopathy and retinal nerve fiber layer (RNFL) screening. The choroidal thickness and RNFL thickness changes in diabetic eyes were evaluated in several studies that used OCT, and these studies reported conflicting results.<sup>15,16</sup>

In this study, we evaluate the choroidal and RNFL thicknesses of diabetic patients with high levels of CRI-1 and compare them with healthy and diabetic

patients without dyslipidemia and variable HbA1c levels.

---

## Methods

This study received approval from the Hitit University Ethics Committee and adhered to the principles of the Declaration of Helsinki. Informed consent was obtained from each patient in the study.

The right eyes of 340 subjects, comprising 173 males and 167 females (mean age,  $56.67 \pm 7.7$  years) without diabetic retinopathy or any other ocular pathologies were included in the study. Patients diagnosed with DM (with and without dyslipidemia) for more than five years were enrolled in the study. Peripheral blood test results were used to evaluate lipid profiles, HbA1c, liver and kidney function tests. Patients with hypertension were excluded from the study. Patients with high triglyceride levels and/or obesity were also specifically excluded from the study in order to distinguish the CRI-1 effect from the effects that may be caused by metabolic syndrome and high triglyceride levels.

Subjects with refractive errors greater than  $\pm 3$  diopters, significant media opacities, intraocular pressure above 21 mmHg, glaucoma, uveitis, and retinal or choroidal disease were excluded from the study. The control group included healthy subjects without ocular or systemic disease and that had normal blood test results.

Five groups of 68 eyes were defined: Group 1 (Control), a control group consisting of healthy subjects; Group 2 (Moderate Glucose Low Lipid Group [MGLL]), DM patients with HbA1c from 7% to 9% and without dyslipidemia (CRI-1 less than 4); Group 3 (Moderate Glucose High Lipid Group [MGHL]), DM patients with HbA1c from 7% to 9% and CRI-1 greater than 4; Group 4 (High Glucose Low Lipid Group [HGLL]), DM patients with HbA1c greater than 9.1% and without dyslipidemia (CRI-1 less than 4); and, Group 5 (High Glucose High Lipid Group [HGHL]), DM patients with HbA1c greater than 9.1% and CRI-1 greater than 4. All patients underwent detailed ophthalmological examination

that included optic disc and enhanced depth choroid imaging using a Spectralis SD-OCT (Heidelberg Engineering, Heidelberg, Germany). Only high-quality scans with a signal strength greater than 20 and without overt misalignment, missing areas, or artifacts were used.

Choroidal thickness (CT) was defined as the distance between the retinal pigmented epithelium (RPE) outer border and the scleral interface. CT measurements were obtained manually at seven positions by a blinded technician (BS) as follows: subfoveal measurement, including three nasal and three temporal measurements to the fovea taken at 500- $\mu$ m intervals. Peripapillary RNFL measurements were obtained through automatic calculation in 7 quadrants. A sample size calculation estimated that 64 eyes would be necessary for a type 1 error rate of 0.05 and a power of 80% to detect a mean difference of 30 microns, with a mean choroidal thickness  $331.13 \pm 45 \mu\text{m}$  (calculated using GPower 3.1). Analysis of variance (ANOVA) (Tukey's post-hoc test for subgroups) was performed using Statistical Package for the Social Science (IBM SPSS Statistics for Windows, Version 24.0). A value of  $P < 0.05$  was considered statistically significant.

## Results

Mean ages of groups 1 to 5 were  $56.1 \pm 5.9$  (35 female/33 male),  $56.5 \pm 8.9$  (34 female/34 male),  $55.8 \pm 8.8$  (32 female/36 male),  $56.9 \pm 6.6$  (32 female/36 male), and  $58.0 \pm 8.2$  (34 female/34 male) years, respectively. There were no statistically significant differences in age and gender between groups.

CT were found to be lower in all DM groups compared with healthy subjects. CT results are reported in Figure 1. In the subfoveal location comparison between group 1 with groups 2 to 5, P values were  $P=0.041$ ,  $P=0.028$ ,  $P=0.01$ , and  $P=0.01$ , respectively. In the nasal location (500 microns from the fovea) comparison between group 1 with groups 2 to 5, P values were  $P=0.005$ ,  $P=0.006$ ,  $P<0.0001$ , and  $P<0.0001$ , respectively. In the nasal location (1000 microns from the fovea) comparison between group 1 with groups 2 to 5, P values were  $P=0.005$ ,  $P=0.006$ ,

$P<0.0001$ , and  $P<0.0001$ , respectively. In the nasal location (1500 microns from the fovea) comparison between group 1 with groups 2 to 5, P values were all  $P<0.0001$ . In the temporal location (500 microns from the fovea) comparison between group 1 with groups 2 to 5, P values were  $P=0.039$ ,  $P=0.01$ ,  $P<0.0001$ , and  $P<0.0001$ , respectively. In the temporal location (1000 microns from the fovea) comparison between group 1 with groups 2 to 5, P values were respectively  $P=0.006$ ,  $P<0.0001$ ,  $P<0.0001$ , and  $P<0.0001$ , respectively. In the temporal location (1500 microns from the fovea) comparison between group 1 with groups 2 to 5, P values were  $P=0.005$ ,  $P<0.0001$ ,  $P<0.0001$ , and  $P<0.0001$ , respectively.

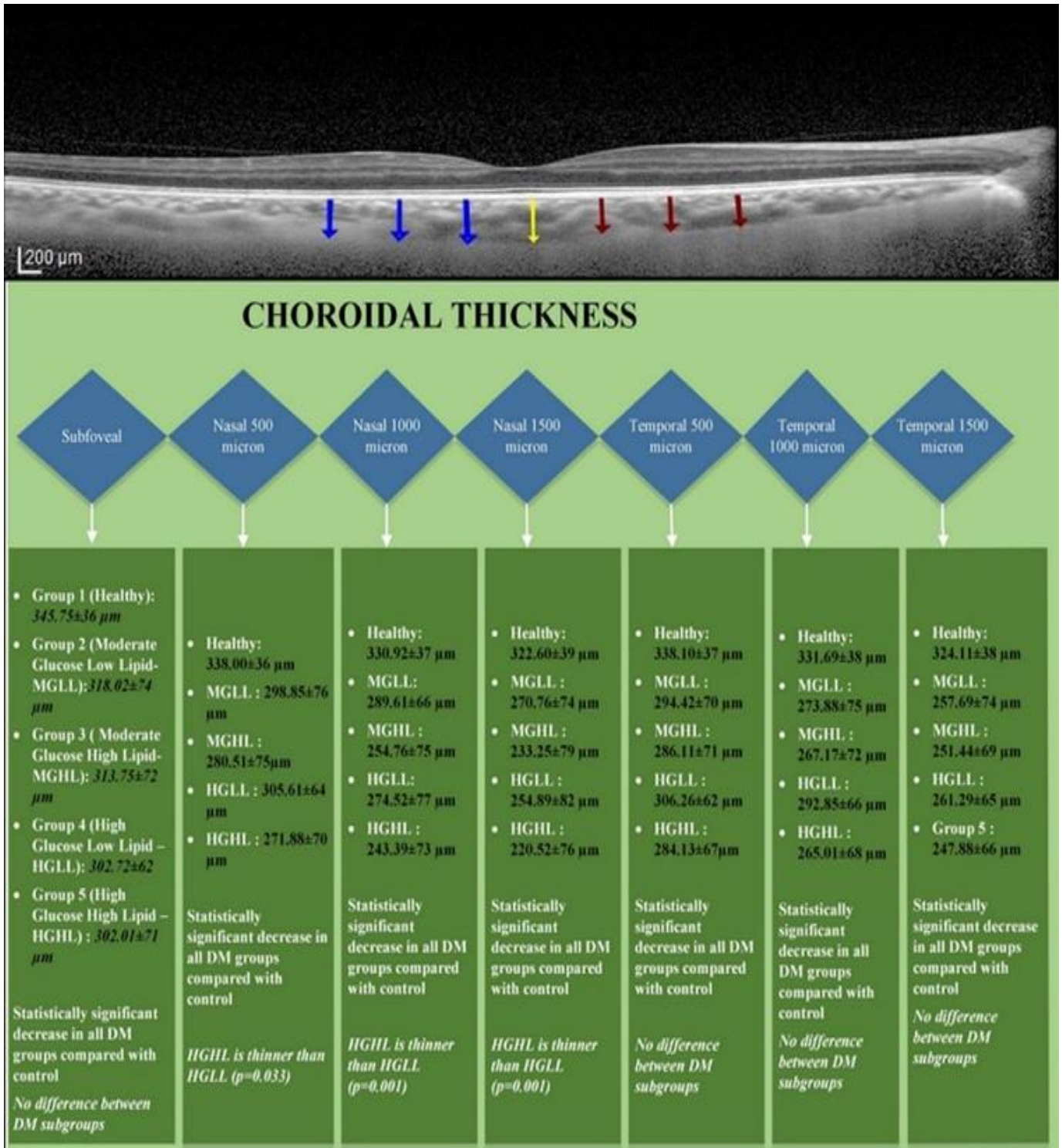
In all nasal areas, group 5 (the HGHL group) choroids were significantly thinner than only group 4 (the HGLL group). P values are given in Figure 1. There was no other statistically significant difference between subgroups.

Retinal nerve fiber layer loss was only seen in the inferior temporal quadrant of all DM patients compared with the control group. There was no statistically significant difference between subgroups. Mean results and P values are reported in Figure 2.

## Discussion

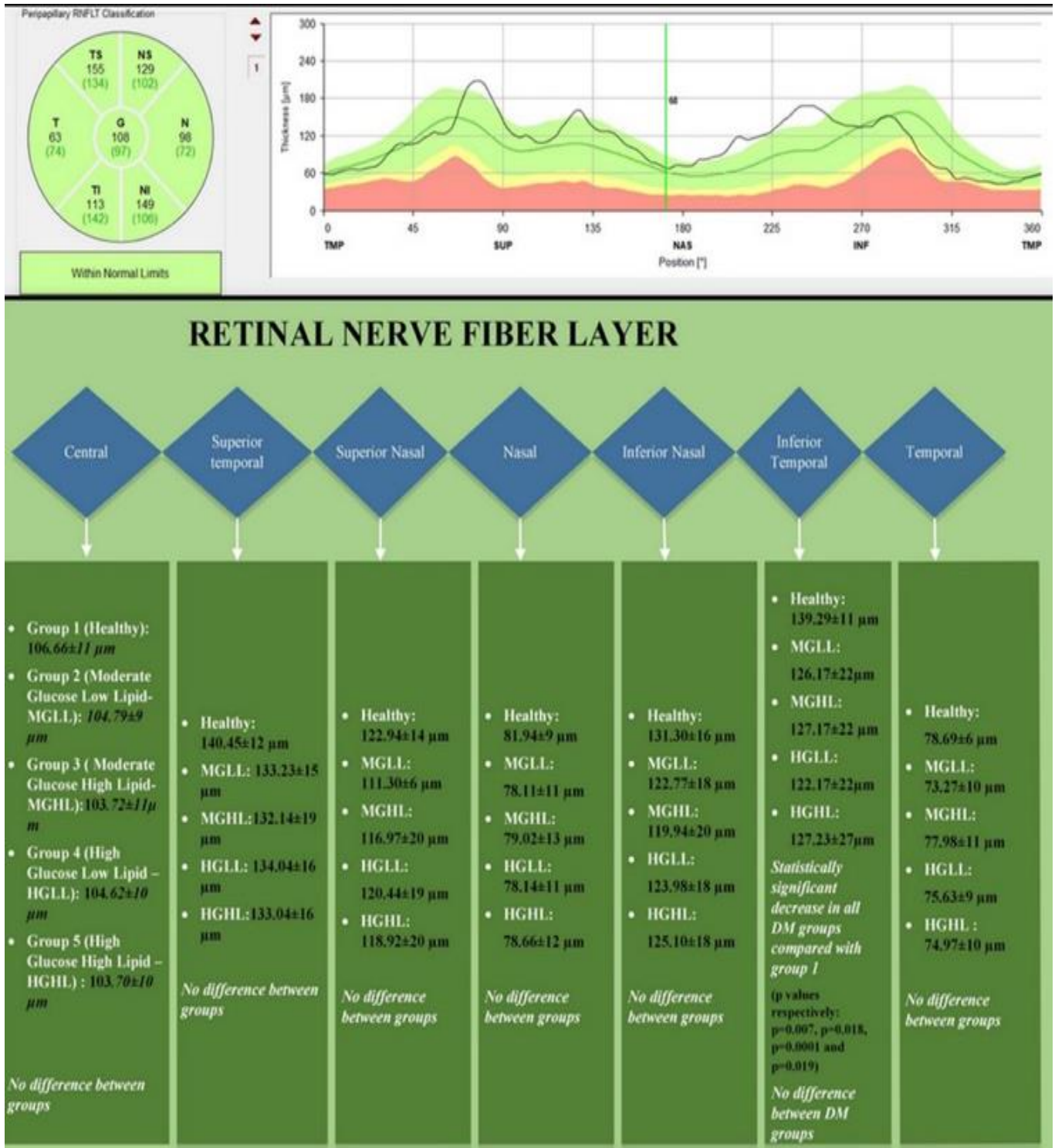
Choroidal changes associated with DM have previously been described in many studies, which may be a contributing factor to DR.<sup>17</sup> Choroidal blood flow was shown to be reduced in DM in studies that used laser Doppler blood flowmetry and indocyanine green angiography.<sup>18</sup> On the other hand, in OCT studies CT varies from study to study. Kase, *et al.* showed that CT decreased in the presence of mild non-proliferative DR and postulated that a continuous high blood sugar state may facilitate vascular damage in the choroid.<sup>19</sup> Gupta, *et al.* found that DM subjects without retinopathy have significantly thinner choroid with fewer vascular areas and reduced vascularity. This contrasts with DR subjects, who had a thicker choroid and significantly larger vascular areas.<sup>20</sup> These are similar to our results that shows an overall CT reduction in DM subjects irrespective of HbA1c or CRI-1. In fact, Chen, *et al.*





**Figure 1**  
Choroidal thickness is shown with OCT enhanced depth choroidal. Subfoveal choroidal thickness (yellow arrow) is compared with nasal macular choroidal thickness at various distances from the fovea (blue arrows) and temporal

macular choroidal thickness at various distances from the fovea (red arrows). Mean choroidal thickness and inter-group comparison results are given below the OCT image.



**Figure 2**  
Retinal nerve fiber layer thickness shown with OCT.  
Results and comparisons of the groups are given below the OCT image.

found that the choroidal thickness was significantly decreased in patients with early-stage DM and postulated that thinning of the choroid may be the earliest sign in the diabetic patients with no clinical retinopathy.<sup>21</sup> Our results support this finding.

In addition to glycemic damage, defects in insulin action and hyperglycemia may lead to changes in plasma lipoproteins in patients with diabetes.<sup>22</sup> Therefore, DM patients are candidates for aggressive dyslipidemia management.<sup>23</sup>

The lipoprotein changes commonly seen in DM include hypertriglyceridemia and reduced plasma HDL cholesterol, and typically have normal low-density lipoprotein-cholesterol (LDL) levels.<sup>22</sup> CRI-1, which is a marker of combined dyslipidemia abnormalities, is used to predict atherosclerotic changes in DM patients.<sup>30</sup> Toth, *et al.* found significant independent associations between dyslipidemia and risks for diabetic microvascular complications, with a 1 mg/dL increase in HDL levels being linked to a 0.5% decrease in microvascular complications.<sup>24</sup> Wong, *et al.* found choroidal thickness was increased in otherwise healthy patients with hypercholesterolemia.<sup>25</sup> In rabbit retinas, hypercholesterolemia was found to cause choroidal thickening and lipid build up at the suprachoroid.<sup>7</sup> However, the effects of dyslipidemia with or without diabetes on the retina has been shown to have variable results across studies.<sup>26,27</sup> It is argued that since the blood-retinal barrier protects the retina against potentially harmful effects of extravasation of plasma lipoproteins, diabetic damage that cause disrupted barriers give way to apolipoprotein B lipoprotein to further damage retinal capillaries, leading to extravasation.<sup>28</sup>

The ADVANCE study showed that lower baseline HDL levels are a significant and independent predictor for the development and progression of diabetic nephropathy, but not retinopathy.<sup>9</sup> In contrast, Larsson *et al.* found associations between higher levels of serum total cholesterol, declining ratios of high density lipoprotein cholesterol to total cholesterol, higher levels of serum lipoprotein-a and more severe retinopathy in diabetes mellitus type 1.<sup>23</sup> Benarous, *et al.* found that serum lipids were not associated with the

presence and severity of DR, mild or moderate diabetic macular edema, or macular thickness.<sup>29</sup> Sacks, *et al.* suggested that the triglycerides and HDL relation with retinopathy may be dependent on other risk factors for microvascular disease, specifically hypertension and HbA1c.<sup>30</sup> Zhong, *et al.* found a significant correlation between higher total cholesterol to triglyceride ratios and diabetic retinopathy.<sup>31</sup>

In this study, we found that nasal choroid thickness is affected by dyslipidemia specifically in high glucose groups. This correlates with the diabetic and lipoprotein damage hypothesis mentioned above—the higher the glucose levels, the more the vascular damage. More vascular damage equals more lipoprotein leakage, which causes additional damage with the increase of said lipids.

In DM patients, RNFL thickness have been shown to be decreased across a multitude of studies, albeit in different segments.<sup>32</sup> For example, Oshitari, *et al.* found prominent loss in the superior quadrant, whereas Takis, *et al.* showed loss in the lower retina.<sup>33,34</sup> Vujosevic, *et al.* found temporal-nasal RNFL loss in diabetic retinopathy patients.<sup>35</sup> Shiba, *et al.* showed that HbA1c effects the blood flow in the optic nerve head.<sup>36</sup> Yucel, *et al.* found that RNFL thickness changes in hypercholesterolemic rats were higher than in controls and in the elevated intraocular pressure group rats. These results were thought to be due to elevated lipid oxidation.<sup>37</sup> Alcalá, *et al.* showed visual perimetry loss in patients with high LDL and low HDL levels.<sup>38</sup> In this study, RNFL loss was only found in the inferior temporal quadrant of all DM patients compared with the control group. This is similar to previous diabetic RNFL damages mentioned above. However, no changes dependent on the CRI-1 levels were found.

There are limitations to this study. First, the study was restricted to information in clinic and hospital records that contained only standard lipid measurements needed for clinical management. It is possible that specific lipoprotein subfractions could be involved in retinopathy. Second, there is no way of knowing the true onset of DM due to its insidious start. Follow-up intervals are also necessary for these



patients to observe the changes with increasing disease duration. In future studies, DM patients with only high triglyceride levels and combined dyslipidemia should be added to these results. In addition, as in every CT studies, multiple reading will be necessary to augment these findings. Also, these groups should be analyzed with the choroidal vascularity index and with OCT-angiography.

## Conclusion

CRI-1 is a marker of combined dyslipidemia abnormalities. It is generally not used as a method for evaluation in serial ophthalmological examinations of diabetic patients. We determined that CRI-1 correlates with the CT of diabetic eyes and can be used as an additional criterion in serial ophthalmological examinations of diabetic patients.

## References

1. Singh VP, Bali A, Singh N, Jaggi AS. Advanced glycation end products and diabetic complications. *Korean Journal of Physiology and Pharmacology* 2014; 18(1): 1-14.
2. Lachin JM, Genuth S, Nathan DM, et al. Effect of glycemic exposure on the risk of microvascular complications in the diabetes control and complications trial--revisited. *Diabetes* 2008; 57(4): 995-1001.
3. Masuch A, Friedrich N, Roth J, et al. Preventing misdiagnosis of diabetes in the elderly: age-dependent HbA1c reference intervals derived from two population-based study cohorts. *BMC Endocrine Disorders* 2019; 19(1): 20.
4. Bressler SB, Odia I, Maguire MG, et al. Factors Associated With Visual Acuity and Central Subfield Thickness Changes When Treating Diabetic Macular Edema With Anti-Vascular Endothelial Growth Factor Therapy: An Exploratory Analysis of the Protocol T Randomized Clinical Trial. *JAMA Ophthalmology* 2019; 137(4): 382-9.
5. Shiragami C, Shiraga F, Matsuo T, et al. Risk factors for diabetic choroidopathy in patients with diabetic retinopathy. *Albrecht von Graefes Archiv fur Klinische und Experimentelle Ophthalmologie* 2002; 240(6): 436-42.
6. Thompson IA, Durrani AK, Patel S. Optical coherence tomography angiography characteristics in diabetic patients without clinical diabetic retinopathy. *Eye* 2019; 33(4): 648-52.
7. Salazar JJ, Ramirez AI, de Hoz R, et al. Alterations in the choroid in hypercholesterolemic rabbits: reversibility after normalization of cholesterol levels. *Experimental Eye Research* 2007; 84(3): 412-22.
8. Torres R, Maia M, Noronha L, et al. Evaluation of choroid and sclera early alterations in hypercholesterolemic rabbits: histologic and histomorphometric study. *Arquivos Brasileiros de Oftalmologia* 2009; 72: 68-74.
9. Morton J, Zoungas S, Li Q, Patel AA, et al. Low HDL cholesterol and the risk of diabetic nephropathy and retinopathy: results of the ADVANCE study. *Diabetes Care* 2012; 35(11): 2201-6.
10. Rema M, Srivastava BK, Anitha B, et al. Association of serum lipids with diabetic retinopathy in urban South Indians--the Chennai Urban Rural Epidemiology Study (CURES) Eye Study-2. *Diabetic Medicine* 2006; 23(9): 1029-36.
11. Baral S, Hamal A, Shyam Bk, et al. Assessment of lipid abnormalities and cardiovascular risk indices in type 2 diabetes mellitus. *Asian Journal of Medical Sciences* 2019; 10: 39-44.
12. Criqui MH, Golomb BA. Epidemiologic aspects of lipid abnormalities. *American Journal of Medicine* 1998; 105(1a): 48s-57s.
13. Montgomery CL, Johnson HM, Johnston TP, Koulen P. Mechanisms underlying early-stage changes in visual performance and retina function after experimental induction of sustained dyslipidemia. *Neurochemical Research* 2018; 43(8): 1500-10.
14. Zhang B, Qiu Q, Yin L, et al. Measurement of retinal function with flash-electroretinography in Chinese patients with hyperlipidemia. *Albrecht von Graefes Archiv fur Klinische und Experimentelle Ophthalmologie* 2014; 252(9): 1385-92.
15. Abadia B, Sunen I, Calvo P, et al. Choroidal thickness measured using swept-source optical coherence tomography is reduced in patients with type 2 diabetes. *PloS One* 2018; 13(2): e0191977.
16. Endo H, Kase S, Takahashi M, et al. Alteration of layer thickness in the choroid of diabetic patients. *Clinical & Experimental Ophthalmology* 2018; 46(8): 926-33.
17. Schocket LS, Brucker AJ, Niknam RM, et al. Foveolar choroidal hemodynamics in proliferative diabetic

- retinopathy. *International Ophthalmology* 2004; 25(2): 89-94.
18. Nagaoka T, Kitaya N, Sugawara R, et al. Alteration of choroidal circulation in the foveal region in patients with type 2 diabetes. *British Journal of Ophthalmology* 2004; 88(8): 1060-3.
  19. Kase S, Endo H, Yokoi M, et al. Choroidal thickness in diabetic retinopathy in relation to long-term systemic treatments for diabetes mellitus. *European Journal of Ophthalmology* 2016; 26(2): 158-62.
  20. Gupta P, Thakku SG, Sabanayagam C, et al. Characterisation of choroidal morphological and vascular features in diabetes and diabetic retinopathy. *British Journal of Ophthalmology* 2017; 101(8): 1038-44.
  21. Chen Q, Tan F, Wu Y, et al. Characteristics of retinal structural and microvascular alterations in early type 2 diabetic patients. *Investigative Ophthalmology & Visual Science* 2018; 59(5): 2110-8.
  22. Goldberg IJ. Diabetic dyslipidemia: causes and consequences. *Journal of Clinical Endocrinology and Metabolism* 2001; 86(3): 965-71.
  23. Larsson LI, Alm A, Lithner F, et al. The association of hyperlipidemia with retinopathy in diabetic patients aged 15-50 years in the county of Umea. *Acta Ophthalmologica Scandinavica* 1999; 77(5): 585-91.
  24. Toth PP, Simko RJ, Palli SR, et al. The impact of serum lipids on risk for microangiopathy in patients with type 2 diabetes mellitus. *Cardiovascular Diabetology* 2012; 11: 109.
  25. Wong IY, Wong RL, Zhao P, Lai WW. Choroidal thickness in relation to hypercholesterolemia on enhanced depth imaging optical coherence tomography. *Retina* 2013; 33(2): 423-8.
  26. Wong TY, Cheung N, Tay WT, et al. Prevalence and risk factors for diabetic retinopathy: the Singapore Malay Eye Study. *Ophthalmology* 2008; 115(11): 1869-75.
  27. Matthews DR, Stratton IM, Aldington SJ, et al. Risks of progression of retinopathy and vision loss related to tight blood pressure control in type 2 diabetes mellitus: UKPDS 69. *Archives of Ophthalmology* 2004; 122(11): 1631-40.
  28. Wu M, Chen Y, Wilson K, et al. Intraretinal leakage and oxidation of LDL in diabetic retinopathy. *Investigative Ophthalmology & Visual Science* 2008; 49(6): 2679-85.
  29. Benarous R, Sasongko MB, Qureshi S, et al. Differential association of serum lipids with diabetic retinopathy and diabetic macular edema. *Investigative Ophthalmology & Visual Science* 2011; 52(10): 7464-9.
  30. Sacks Frank M, Hermans Michel P, et al. Association between plasma triglycerides and high-density lipoprotein cholesterol and microvascular kidney disease and retinopathy in type 2 diabetes mellitus. *Circulation* 2014; 129(9): 999-1008.
  31. Zhong Y, Yue S, Wu J, et al. Association of the serum total cholesterol to triglyceride ratio with diabetic retinopathy in Chinese patients with type 2 diabetes: a community-based study. *Diabetes Therapy* 2019; 10(2): 597-604.
  32. Cao D, Yang D, Yu H, et al. Optic nerve head perfusion changes preceding peripapillary retinal nerve fibre layer thinning in preclinical diabetic retinopathy. *Clinical & Experimental Ophthalmology* 2019; 47(2): 219-25.
  33. Oshitari T, Hanawa K, Adachi-Usami E. Changes of macular and RNFL thicknesses measured by Stratus OCT in patients with early stage diabetes. *Eye* 2009; 23(4): 884-9.
  34. Takis A, Alonistiotis D, Panagiotidis D, et al. Comparison of the nerve fiber layer of type 2 diabetic patients without glaucoma with normal subjects of the same age and sex. *Clinical Ophthalmology* 2014; 8: 455-63.
  35. Vujosevic S, Martini F, Cavarzeran F, et al. Macular and peripapillary choroidal thickness in diabetic patients. *Retina* 2012; 32(9): 1781-90.
  36. Shiba C, Shiba T, Takahashi M, et al. Relationship between glycosylated hemoglobin A1c and ocular circulation by laser speckle flowgraphy in patients with/without diabetes mellitus. *Albrecht von Graefes Archiv fur Klinische und Experimentelle Ophthalmologie* 2016; 254(9): 1801-9.
  37. Yucel I, Akar Y, Yucel G, et al. Effect of hypercholesterolemia on inducible nitric oxide synthase expression in a rat model of elevated intraocular pressure. *Vision Research* 2005; 45(9): 1107-14.
  38. Alcalá A, Jansen S, Farkouh ME, Morell M. Hypercholesterolemia is associated with visual field alterations detectable with computerized perimetry. *Atherosclerosis* 2007; 195(1): e167-71.