

Bird pecking ocular injury caused by a native Malayan bird

Logeswari Krishna;¹ Nur Aisyah Zakraia;² Sujaya Singh;¹ Mary May Choo;¹ Lott Pooi Wah¹

¹Ophthalmology Department, Eye Research Center, University of Malaya, Kuala Lumpur, Malaysia.

²Queen Elizabeth Hospital, Kota Kinabalu, Malaysia.

Abstract

Eye injuries resulting from bird pecking are rare but may cause permanent blindness. We report a case of penetrating ocular injury following a peck by a white-breasted waterhen. A 13-year-old girl presented with painful visual loss in her left eye after being pecked by her pet bird. She sustained a central corneal laceration and traumatic cataract in her left eye. Primary closure of corneal laceration was performed without complication. Broad spectrum topical and intravenous antibiotics were administered. After two weeks, she developed a mature white cataract. Subsequently, she underwent lens aspiration with intraocular lens implantation. Her vision improved drastically from 20/2400 to 20/60. Precautions should be taken while handling birds, especially when children are handling birds, in order to prevent any ocular injury. Parents play a vital role in preventing their child from getting injured by birds.

Introduction

Bird pecking eye injuries are relatively rare.^{1,2} Birds as such are known to be harmless based on an assumption that they will take flight if frightened. Despite their tendency to take flight, many birds show aggressive behavior related to territoriality or breeding.³ The face and the eyes are the most vulnerable areas when the birds attack humans.³ The iris colour which contrasts the rest of the face and the shiny cornea as well as the movements of the eyes are

strong features of attraction for the attacking birds.⁴ Ocular injuries caused by birds are generally penetrating eye injuries which may result in blindness. We report a case of penetrating ocular injury, with a fairly good visual outcome, caused by the pecking of a white-breasted waterhen. In a search of the peer-reviewed medical literature (using MEDLINE and cross-referenced literature), this study may be the first to report ocular damage via a bird in Malaysia.

Case Report

A 13-year-old girl presented with painful visual loss in the left eye after she was pecked by her pet bird while she was feeding it. On presentation, her best corrected visual acuity (BCVA) in the left eye was 20/2400 and in the right eye was 20/20. She sustained a full thickness central linear corneal laceration, measuring about five millimeters vertically (Figure 1). On the same day, she underwent corneal suturing and anterior chamber wash out of her left eye under general anesthesia. Intravitreal vancomycin (2 milligrams in 0.1 milliliters) and ceftazidime (2 milligrams in 0.1 milliliters) were given intraoperatively as endophthalmitis prophylaxis. She was treated with 400 mg of intravenous ciprofloxacin. Postoperatively, she was treated with topical 0.5% moxifloxacin and topical 0.1% dexamethasone.

On examination 2 weeks later, she was noted to have a white traumatic cataract (Figure 2). She then

Correspondence:
Lott Pooi Wah
Ophthalmology Department
University of Malaya
Kuala Lumpur, Malaysia
Email: lottpw@yahoo.com
Phone: + 60 17 982 5096

Conflict of Interest: The authors report no conflicts of interest.

Contributions: All authors contributed equally.

Accepted for Publication: October, 2020

This work is licensed under a Creative Commons Attribution Non-Commercial 3.0 License (CC BY-NC 3.0).

©Copyright Krishna, et al., 2020.

License Ophthalmoscience Publishers, USA

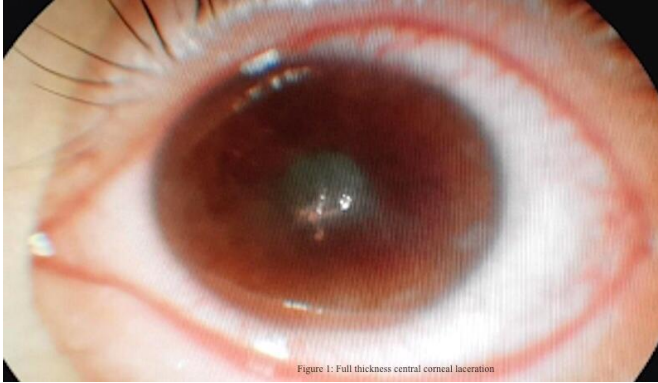

Figure 1
Photograph of the full thickness central linear corneal laceration of the left eye.

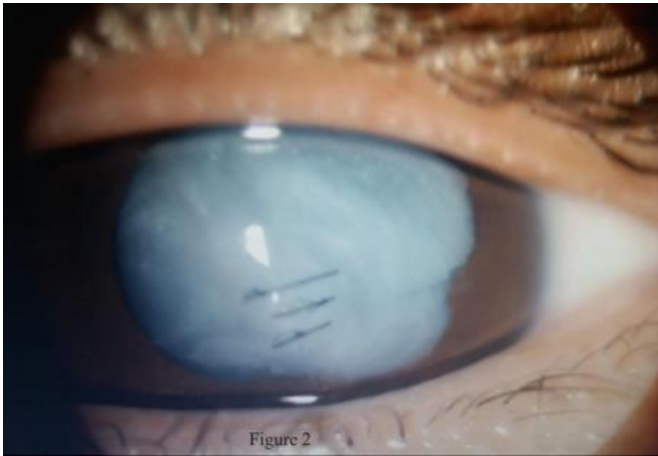


Figure 2
Photograph of white traumatic cataract in left eye 2 weeks after pecking of bird.

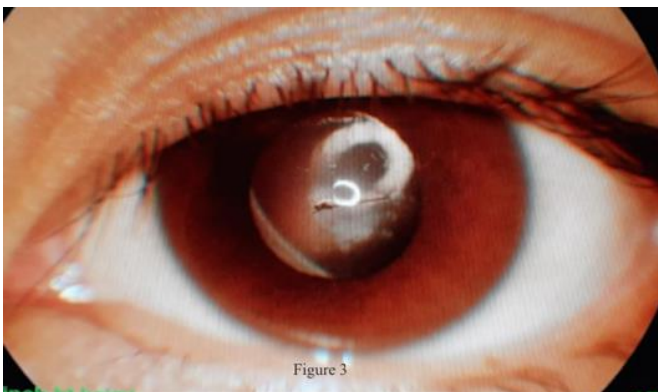


Figure 3
Photograph of the left eye at 6 months after surgery showing with minimal central corneal scar.

underwent left eye lens aspiration with intraocular lens implantation under general anesthesia. At 6 months postoperative, there was minimal central corneal scar (Figure 3). Her BCVA in the left eye was 20/60.

Discussion

Although, ocular injuries caused by bird pecking are rare, they may cause blindness. In a case series reviewed by K hl, a total of 14 patients were pecked by birds from 1875 through 1970 in Germany.⁵ All were penetrating ocular injury and some caused permanent ocular complications including blindness. Abdulla and Alkhalifa reported a case globe rupture of a patient in Bahrain after being attacked by a bird.⁶ That patient was given broad spectrum antimicrobial and underwent corneal transplant and intraocular lens implantation, after which visual acuity improved from counting finger to 20/200. In another case reported by Chaudhry, *et al.* a patient had severe visual loss after being attacked by an ostrich, in which he sustained globe rupture with multiple scleral lacerations.⁷ In another case reported by Tyson and Srinivasan, a young man was pecked by a bird while trying to tame it; his ocular injury was limited to a corneal abrasion which later resolved without complications, using topical moxifloxacin.⁸

These cases demonstrate that bird pecking ocular injuries can range from a severe penetrating injury causing blindness to a milder injury with only corneal abrasion. In our case, it was a corneal laceration with traumatic cataract, which responded well with primary closure, lens aspiration, and broad-spectrum antibiotics.

The patient in our case report was pecked by her own pet, a white-breasted waterhen which is called “Ke-ru-ak” by local people. This species is found throughout the Indian subcontinent (including the British Indian Ocean Territory) and South East Asia, as far as the Lesser Sundas, Indonesia. This species has a varied diet which includes insects, worms, spiders, molluscs and even small fishes, as well as grass seeds, roots, and shoots of marsh plant. These birds are

normally seen alone or in pairs, but have been described as being aggressive as interspecies fights often occur.⁹ If disturbed, the bird tends to run into cover rather than taking fight.⁹ There has been no research available that isolates specific microorganisms from the white-breasted waterhen's beak. Hence, in our case, a broad-spectrum antibiotic coverage was used and visual outcome was acceptable for the patient. Our case report highlights the danger that may be posed by birds in general. This is especially important in children, as birds and nondomestic mammals are responsible for the most severe ocular injuries.¹⁰ Parents should be aware of the territorial behaviour of the birds before allowing their children to handle them.

Conclusions

Eye injuries resulting from bird pecking are rare but may cause permanent blindness. Precautions should be taken while handling birds, more so in children. Parents play a vital role in preventing any injury to their children through birds or other nondomestic animals.

References

1. Al-Sharif EM, Alkharashi AS. An unusual case of penetrating eye injury caused by a bird: a case report with review of the pertinent literature. *Saudi Journal of Ophthalmology* 2019; 33(2): 196-9.
2. Tabatabaei SA, Soleimani M, Behrouz MJ. Bird attack ocular injuries. *Retina* 2018; 38(5): 945-50.
3. Lekse Kovach J, Maguluri S, Recchia FM. Subclinical endophthalmitis following a rooster attack. *Journal of AAPOS* 2006; 10(6): 579-80.
4. Muller L, Kohnen T. Scleral and corneal laceration with iris prolapse caused by an eagle claw. *Graefe's Archive for Clinical and Experimental Ophthalmology* 2005; 243(4): 377-9.
5. Kuhl W. [Eye injuries caused by birds]. *Klinische Monatsblätter für Augenheilkunde* 1970; 157(6): 810-5.
6. Abdulla HA, Alkhalifa SK. Ruptured globe due to a bird attack. *Case Reports in Ophthalmology* 2016; 7(1): 112-4.
7. Chaudhry IA, Al-Sharif AM, Hamdi M. Severe ocular trauma caused by an ostrich. *British Journal of Ophthalmology* 2005; 89(2): 250-1.
8. Tyson C, Srivinishan S. A peck of affection or a peck of aggression: case report of an eye injury due to the black naped oriole. *Advances in Ophthalmology and Visual System* 2017; 6(1): 00169.
9. Whistler, H. (1963) *Popular Handbook of Indian Birds*. Oliver and Boyd, Edinburgh.
10. Yardley AM, Hoskin AK, Hanman K, et al. Animal-inflicted ocular and adnexal injuries in children: a systematic review. *Survey of Ophthalmology* 2015; 60(6): 536-46.